

Eleonora de Paula Amaral

Análise histopatológica do tecido epitelial e da musculatura da
língua de ratos submetidos à inalação da fumaça do tabaco

Histopathological analysis of the epithelial tissue and tongue
musculature of rats submitted to inhalation of tobacco smoke

Uberaba

2018

Universidade de Uberaba
Eleonora de Paula Amaral

Análise histopatológica do tecido epitelial e da musculatura da língua de ratos submetidos à
inalação da fumaça do tabaco

Dissertação apresentada como parte dos requisitos
para obtenção do título de Mestre em Odontologia
do Programa de Pós-Graduação em odontologia –
Mestrado da Universidade de Uberaba.

Área de concentração: Biopatologia

Uberaba

2018

Catálogo elaborado pelo Setor de Referência da Biblioteca Central-UNIUBE

Amaral, Eleonora de Paula.

A13a Análise histopatológica do tecido epitelial e da musculatura da língua de ratos submetidos à inalação da fumaça do tabaco / Eleonora de Paula Amaral. – Uberaba-MG, 2018.
72 f. il. : color.

Dissertação (mestrado) – Universidade de Uberaba.
Programa de Pós-graduação em Odontologia.
Orientadora: Prof^ª. Dr^ª. Sanivia Aparecida de Lima Pereira.

1. Boca – Doenças. 2. Fumo – Vício. 3. Animais – Experimentação. 4. Fumantes. I. Universidade de Uberaba.
Programa de Pós-graduação em Odontologia. II. Título.

CDD: 616.3107

ELEONORA DE PAULA AMARAL

“ANÁLISE HISTOPATOLÓGICA DO TECIDO EPITELIAL E DA MUSCULATURA DA LÍNGUA DE RATOS SUBMETIDOS À INALAÇÃO DA FUMAÇA DO TABACO”

Dissertação apresentada como parte dos requisitos para obtenção do título de Mestre em Odontologia do Programa de Pós-Graduação em Odontologia - Mestrado da Universidade de Uberaba.

Área de concentração: Biopatologia

Aprovado (a) em: 19/02/2018

BANCA EXAMINADORA:



Profª Drª Sanívia Aparecida de Lima Pereira
Orientadora
Universidade de Uberaba



Prof. Dr. Cesar Penazzo Lepri
Universidade de Uberaba



Profª. Drª. Mara Lúcia da Fonseca
Universidade Federal do Triângulo Mineiro

À minha mãe **Lidia** e ao meu pai **Vanderlei**;
Aos meus irmãos **Domingos** e **Berenice**;
À minha afilhada **Manuela**;
E ao meu namorado **Flávio**.

Agradecimentos

Ao Programa de Pós-graduação em Odontologia e à todos os seus professores e funcionários, em específico ao coordenador **Prof. Dr. Cesar Penazzo Lepri**, e à secretária **Flávia Michele da Silva** pelo apoio, paciência e profissionalismo exemplar.

À minha orientadora, **Prof^a. Dr^a. Sanivia Aparecida de Lima Pereira**, pessoa com a qual eu pude aprender bastante, o meu muito obrigada pela convivência, pela orientação, pela paciência, compreensão e por todos os conhecimentos compartilhados durante estes dois anos de mestrado.

Ao **Prof. Rodrigo Rosa** (UFTM) e a **Dr^a Renata Etchebehere** (Hospital das Clínicas/UFTM), pelas orientações à respeito da parte metodológica e auxílio nas análises deste trabalho.

À **Prof^a. Dr^a. Ruchele Dias Nogueira Geraldo Martins** e ao **Prof. Dr. Benito Miranzi** pela orientação durante a graduação, o que me incentivou na realização deste Curso de Mestrado.

À **Me. Camilla Beatriz** e **Dr^a. Eliângela Cobo** (Hospital das Clínicas/UFTM) pela colaboração durante as etapas laboratoriais

Resumo

Introdução: O tabagismo é um fator de risco para sérios problemas de saúde que podem acometer também os fumantes passivos. Além disso, está associado à várias alterações nos tecidos da cavidade oral. **Objetivo:** Avaliar a presença de displasia epitelial, de inflamação, a porcentagem de colágeno, a densidade de mastócitos e a intensidade de células imunomarcadas por anti-HIF-1 α na musculatura lingual de ratas expostas à fumaça do cigarro. **Metodologia:** Vinte e sete ratos albinos fêmeas *Wistar* foram divididos em três grupos: ratos não expostos à inalação da fumaça do tabaco (Grupo controle) (n=7); ratos expostos à inalação da fumaça do tabaco durante 30 dias (TAB 30) (n=10); e ratos expostos à inalação da fumaça do tabaco durante 45 dias (TAB 45) (n=10). Com o auxílio de um equipamento, os animais foram expostos à fumaça de quatro cigarros por dia no interior de câmaras cilíndricas. Os intervalos entre o tempo de exposição à fumaça e ao ar ambiente eram controlados por uma bomba peristáltica. Semanalmente o peso dos animais e o percentual de monóxido de carbono de cada câmara cilíndrica eram avaliados. Ao final do experimento os animais foram submetidos à eutanásia com dose excessiva de Tiopentato de sódio via intraperitoneal com posterior coleta de sangue para dosagem de cotinina plasmática. Posteriormente as línguas dos animais foram coletadas, processadas histopatologicamente e coradas pelos corantes Hematoxilina e eosina, Picrossírius e Azul de Toluidina. Os cortes adicionais foram utilizados para processamento imunohistoquímico para HIF-1 α . Todas as análises foram realizadas isoladamente nos três terços da língua com auxílio de microscopia de luz comum. As análises estatísticas foram realizadas utilizando os testes estatísticos ANOVA e Kruskal-Wallis e pós testes de Tukey e de Dunn. Foram utilizados ainda, os testes de correlação de Pearson e de Spearman. Todas as análises foram realizadas utilizando o nível de significância de 5%. **Resultados:** Nos grupos expostos à fumaça do cigarro foi observada menor porcentagem de colágeno, maior densidade de mastócitos e maior intensidade de células imunomarcadas por anti-HIF-1 α . Não foi observada displasia epitelial. A inflamação foi observada em apenas dois casos. Houve também correlação positiva e significativa entre a porcentagem de colágeno e densidade de mastócitos. **Conclusão:** Sabendo da importância da musculatura lingual na deglutição, mastigação e fala o presente estudo chama a atenção para prevenção contra a exposição passiva ao tabaco.

Palavras-Chave: fumaça lateral, fumantes passivos, língua, ratos, tabaco.

Abstract:

Introduction: Smoking is a risk factor for serious health problems that can also affect passive smokers. Furthermore, it is associated with several changes in the tissues of the oral cavity.

Objective: To evaluate the presence of epithelial dysplasia, inflammation, the percentage of collagen, the mast cell density and the anti-HIF-1 α -immunoregulated cell intensity in the lingual musculature of rats.

Methods: Twenty-seven Wistar female albino rats were divided into three groups: rats not exposed to inhalation of tobacco smoke (control group) (n = 7); rats exposed to inhalation of tobacco smoke for 30 days (TAB 30) (n = 10); and rats exposed to inhalation of tobacco smoke for 45 days (TAB 45) (n = 10). With the aid of equipment, the animals are exposed to smoke of four cigarette per day inside cylindrical chambers, the smoke puffs and the intervals between the time of exposure to smoke and the time of exposure to ambient air were controlled by a peristaltic pump. Weekly the weight of the animals and the percentage of carbon monoxide of each cylindrical chamber were evaluated. At the end of the experiment, the animals were submitted to euthanasia with excessive dose of sodium thiopentate via intraperitoneal and blood samples were collected for dosage of plasma cotinine. Subsequently the tongue of the animals with collected, histopathologically processed and stained by dyes Hematoxylin and eosin, Picrossírius and Toluidine Blue. Additional cuts were used for the immunohistochemical processing for HIF-1 α . All analyzes were performed separately in the different thirds of the tongue and with the aid of light microscopy. Statistical analyzes were performed using the statistical tests ANOVA and Kruskal-Wallis and post tests of Tukey and Dunn. Pearson and Spearman correlation tests were also used. All analyzes were performed using the significance level of 5%.

Results: In the groups exposed to cigarette smoke, a lower percentage of collagen, a higher density of mast cells and a higher intensity of anti-HIF-1 α -immunolabelled cells were observed. No epithelial dysplasia was observed. Inflammation was observed in only two cases. There was also a positive and significant correlation between a percentage of collagen and mast cell density.

Conclusion: Knowing the importance of lingual musculature in swallowing, mastication and speech of the present study calls attention to prevention against passive exposure to tobacco.

Keywords: passive smoker, rats, second hand smoke, tobacco, tongue.

Lista de Figuras

- Figura 1. A.** Desenho esquemático do equipamento utilizado para exposição dos ratos à fumaça do tabaco. Bomba peristáltica (1), tubulação (2), cigarro (3), recipiente para distribuição da fumaça (4), câmaras cilíndricas (5). **B.** Desenho esquemático da caixa externa isolante (6) e do exaustor (7) **57**
- Figura 2.** (A) Imagem despolarizada de fibras colágenas entre a musculatura lingual do grupo controle, coloração Picrossírius, aumento de 400x. (B) Imagem polarizada de fibras colágenas entre a musculatura lingual do grupo controle, coloração Picrossírius, aumento de 400x **66**
- Figura 3.** Comparação do peso final entre os grupos controle, TAB 30 e TAB 45; teste ANOVA. $p < 0.0001$ **66**
- Figura 4.** (A) Epitélio dorsal normal no terço médio da língua, animal do grupo TAB 30, coloração HE, aumento de 400x. (B) Infiltrado inflamatório no terço apical da língua, animal do grupo TAB 45, coloração HE, aumento de 400x **67**
- Figura 5.** Comparação da porcentagem de colágeno da musculatura lingual entre grupos controle, TAB 30 e TAB 45; teste Kruskal-Wallis. (A) terço apical, $p < 0.0001$; (B) terço médio, $p = 0.4752$; (C) terço posterior, $p < 0.0001$. * Indica diferença significativa entre os grupos **68**
- Figura 6.** Comparação da densidade de mastócitos na musculatura lingual entre os grupos controle, TAB 30 e TAB 45; teste ANOVA. (A) terço apical, $p = 0.0608$; (B) terço médio, $p = 0.0163$; (C) terço posterior, $p = 0.0007$. * Indica diferença significativa entre os grupos **69**
- Figura 7.** Mastócitos no terço apical do grupo TAB 45, coloração azul de toluidina, aumento 400x **70**

Figura 8. (A) Correlação entre a densidade de mastócitos e a porcentagem de colágeno na musculatura lingual de ratas expostas à fumaça do tabaco por 30 dias; Correlação de Spearman, $p < 0.0001$. (B) Correlação entre a densidade de mastócito e a porcentagem de colágeno na musculatura lingual de ratas expostas à fumaça do tabaco por 45 dias; Correlação de Pearson, $p < 0.0001$ **70**

Figura 9. Comparação da imunomarcaçãopara HIF-1 α entre entre os grupos controle, TAB 30 e TAB 45; teste Kruskal-Wallis. (A) terço apical, $p = 0.0036$; (B) terço médio, $p = 0.0029$; (C) terço posterior, $p = 0.0007$. * Indica diferença significativa entre os grupos **71**

Figura 10. Imunomarcaçãoforte para HIF-1 α em fibras musculares linguais do grupo TAB 45, aumento 400x **72**

Lista de Abreviaturas

pH – Potencial hidrogeniônico

MMC – Mastócitos de mucosa

CTMC – Mastócitos de tecido conjuntivo

SpO₂ – Saturação de Oxigênio

HIF-1 – Fator de Transcrição 1 Induzido por hipóxia

HIF-1 α – Fator de Transcrição 1 Induzido por hipóxia alfa

HIF-1 β – Fator de Transcrição 1 Induzido por hipóxia beta

EPO – Eritropoietina

VEGF - Fator de crescimento endotelial vascular

ALDA – Aldolase A

ENO1 – Enolase 1

LDHA – Lactato desidrogenase A

PFKL - Fosfofructoquinase L

PGK1 - Fosfogliceratoquinase 1

ATP - Adenosina trifosfato

REDD1 – Proteína regulada em danos ao DNA e desenvolvimento 1

MMP-9 – Metaloproteinase de Matriz 9

HO-1 – Heme oxigenase

TAB 30 – Ratos Expostos à fumaça do Tabaco por 30 dias

TAB 45 - Ratos Expostos à fumaça do Tabaco por 45 dias

mg – Miligrama

g – gramas

kg - Kilograma

mL – Mililitro

ng – Nanograma

μm – Micrometro

μm^2 – Micrometro quadrado

Índice

Introdução Geral	13
Capítulo 1. Histopathological analysis of the epithelial tissue and tongue musculature of rats submitted to inhalation of tobacco smoke	23
Abstract	24
Introduction	25
Methods	26
<i>Animals and groups</i>	26
<i>Exposure of rats to tobacco smoke</i>	27
<i>Evaluation of weight, euthanasia and blood sampling</i>	28
<i>Dosage of cotinine</i>	28
<i>Collection of tongues samples, histochemical and immunohistochemical processing</i>	29
<i>Analysis of dysplasia and inflammation</i>	29
<i>Determination of the percentage of collagen</i>	29
<i>Determination of mast cell density</i>	30
<i>Immunohistochemical processing and analysis of anti-HIF-1α immunolabelled cells</i>	30
<i>Statistical analysis</i>	30
Results	31
Discussion	32
Acknowledgments	35
Declaration of conflict of interest	35
References of the article	36
Conclusão	43
Referências da Dissertação	44
Anexos	56
Apêndice	66

Introdução

De acordo com a Organização Mundial de Saúde (OMS) o tabagismo é considerado uma doença crônica decorrente da dependência da nicotina (WHO/Tobacco, 2015), estando inserido no CID (Classificação Internacional de Doenças) desde 1997 dentro dos grupos de transtornos mentais e de comportamentos decorrentes do uso de fumo (CID10 F17) e dos problemas relacionados com o uso do tabaco (CID10 Z72.0) (DATASUS, 2008). Esse hábito representa o maior fator de risco modificável associado a sérios problemas de saúde como câncer, doenças cardiovasculares, doenças respiratórias e infertilidade (COLOMBO et al., 2014).

A OMS estima que exista aproximadamente um bilhão de fumantes no mundo e cinco milhões de mortes atribuídas direta ou indiretamente ao uso do tabaco. Caso não haja mudança no modelo de consumo de tabaco, o número de fumantes passará de 1,6 bilhões e o número de mortes anuais chegará a 10 milhões nos próximos três anos. Portanto, o hábito de fumar cigarro é uma importante ameaça à saúde pública em todo o mundo e uma das principais causas evitáveis de mortes (WHO/Tobacco, 2015).

Dados de 2004 apontaram que do total mundial de não fumantes expostos à fumaça proveniente do cigarro de terceiros, 40% eram crianças, 33% homens e 35% mulheres (OBERG et al., 2011). Além disso, 10% das mortes relacionadas ao tabaco são de não fumantes expostos à fumaça de cigarro (WHO | Tobacco, 2015).

Em 2008 no Brasil, o Instituto Brasileiro de Geografia e Estatística (IBGE) divulgou os dados da Pesquisa Especial de Tabagismo, os quais apontaram que 17,2% da população brasileira com mais de 15 anos de idade fumavam derivados de tabaco. A pesquisa revelou ainda que 27,9% dos brasileiros não fumantes eram expostos à fumaça produzida por cigarro de terceiros, principalmente no ambiente familiar (IBGE, 2008).

Ainda no Brasil, em 2013, a Pesquisa Nacional de Saúde (PNS) divulgou que 15% da população com mais de 18 anos era usuária de derivados de tabaco. Além disso foi demonstrado nessa pesquisa que 10,7% da população era de não fumantes expostos à fumaça no ambiente familiar e 13,5% de não fumantes expostos à fumaça no ambiente de trabalho (PNS, 2013).

A fumaça do cigarro é classificada em duas categorias, a fumaça central ou principal e a fumaça periférica ou lateral. A fumaça central é gerada durante as tragadas e produzida em altas temperaturas (acima de 950°C), sendo a principal fonte de exposição dos próprios usuários do

cigarro, ou seja, dos fumantes ativos. A fumaça lateral, por sua vez, é gerada durante a queima lenta do cigarro que ocorre no intervalo entre as tragadas com temperatura mais baixa em relação à fumaça central (cerca de 350°C), sendo considerada como a fonte de exposição dos indivíduos que involuntariamente inalam a fumaça presente no ambiente, também conhecidos como fumantes passivos (SOPORI ; KOZAK, 1998; MELLO et al., 2005; VALENTI et al., 2011).

A fumaça é constituída por várias substâncias químicas diferentes e em proporções inexatas, as quais estão distribuídas entre elementos particulados, que ficam retidos no filtro do cigarro e elementos gasosos, que atravessam o filtro (HOFFMANN et al., 2001; PERFETTI; RODGMAN, 2011).

Segundo estimativa, a fumaça do cigarro contém aproximadamente 5600 componentes individuais (PERFETTI; RODGMAN, 2011), dos quais, pelo menos 158 apresentam propriedades carcinogênicas ou tóxicas, dentre elas a nicotina, o acetaldeído, o benzeno, o formaldeído, os metais, policíclicos aromáticos, a acroleína, o monóxido de carbono e o dióxido de carbono (FOWLES; DYBING, 2003; THORNE; ADAMSON, 2013).

Os elementos tóxicos presentes na fumaça do cigarro, além de representar ameaças aos fumantes ativos, devido à sua inalação direta, também aumentam os riscos para a saúde dos fumantes passivos, isso porque a fumaça lateral apresenta quase a mesma quantidade de elementos totais que a fumaça central. Portanto, o risco de doenças relacionadas com o tabagismo também aumenta nesses indivíduos (BEHERA, et al., 2014). Um estudo de revisão relatou uma série de pesquisas que demonstraram que a fumaça lateral é mais tóxica e mais tumorigênica quando comparada à fumaça principal (SCHICK, S; GLANTZ, 2005).

A fumaça lateral pode levar ao aumento da agregação plaquetária, à disfunção endotelial, ao aumento da rigidez arterial e do estresse oxidativo, ao mesmo tempo em que leva à diminuição de antioxidantes endógenos, além de causar inflamação, diminuir a produção de energia e a vazão parassimpática para o coração. Estes mecanismos desencadeiam efeitos negativos no sistema cardiovascular de indivíduos expostos à essa fumaça, como lesão endotelial, trombose e aterosclerose (BARNOYA; GLANTZ, 2005).

Imediatamente à inalação da fumaça resultante da combustão do cigarro, os indivíduos expostos já começam a sentir os efeitos deletérios como irritação dos olhos, nariz, garganta e pulmões, dor de cabeça, vertigem, elevação da pressão arterial e angina (COELHO et al., 2012).

Vários metabólitos do cigarro como tiocianato, monóxido de carbono, nicotina, cotinina, além de carboxiemoglobina são utilizados como biomarcadores para avaliar o grau de tabagismo e a exposição à fumaça em fumantes ativos e passivos, entretanto, muitos deles apresentam baixa especificidade (JARVIS et al., 1987). A nicotina por exemplo, apresenta a meia vida relativamente curta, de 2 horas aproximadamente, o que dificulta a sua detecção nos fluidos corporais e quantificação da exposição ao tabaco (FEYERABEND et al., 1986; MELLO et al., 2005). A carboxihemoglobina, sofre influência do monóxido de carbono presente no ambiente, comprometendo assim sua fidedignidade (MELLO et al., 2005). O monóxido de carbono e o tiocianato, por sua vez, não são marcadores específicos para a fumaça do cigarro (FEYERABEND et al., 1986).

Dessa forma, a cotinina tem sido o principal marcador biológico utilizado para avaliar o consumo de tabaco, bem como para o controle de sua abstinência (JARVIS et al., 1987). A cotinina é o principal metabólito da nicotina, o qual é oxidado no fígado pela enzima CYP2A6 (Citocromo P450, família 2, subfamília A, polipeptídeo 6) e posteriormente distribuídos para os vários fluidos humanos (YOSHIDA et al., 2002; JUNG et al., 2012; RAJA et al., 2016). Das amostras utilizadas para avaliar as taxas de cotinina, os níveis na saliva, no soro, no plasma e na urina são os mais apropriados pois estão correlacionados com a nicotina total absorvida (PETERSEN et al., 2010).

A escolha da cotinina como biomarcador se dá em virtude de sua especificidade para a exposição ao tabaco, por possuir restrita distribuição nos fluidos corporais, além de apresentar baixa taxa metabólica e meia-vida na circulação 10 vezes mais longa, quando comparado à nicotina. Além disso a cotinina pode ser facilmente coletada de forma não invasiva caso sejam utilizadas amostras de saliva e urina (MELLO et al., 2005; JUNG, S. et al., 2012). Além de que, nos tabagistas, a concentração sérica de cotinina se mantém constante durante todo o dia (MELLO et al., 2005).

Mesmo após a interrupção do uso do cigarro, a fumaça secundária e conseqüentemente a nicotina e outras substâncias tóxicas e carcinogênicas continuam presentes por seis meses nos dedos, na urina e nos ambientes habitados pelos usuários. Dessa forma, os fumantes passivos também continuam expostos à essas substâncias prejudiciais por igual período de tempo (MATT et al., 2016).

A cavidade oral é a porta de entrada do corpo humano, sendo diretamente exposta à fumaça proveniente do tabaco. Dessa forma, o tabagismo é um importante fator de risco para muitas doenças e condições adversas orais como câncer oral, lesões pré-cancerosas, estomatite nicotínica, melanoses, candidose oral, hiperqueratose, gengivite, periodontite, manchas em dentes e restaurações, perda de implantes dentários, peri-implantite e halitose além de contribuir para um mal prognóstico nos tratamentos odontológicos (GELSKEY, 1999; SHAM et al., 2003; SUSIN et al., 2004; CORRAINI et al., 2008; REIBEL, 2003; FURUKAWA et al., 2013; SHAMMARI et al., 2016).

Essas alterações orais provocadas pelo tabagismo provavelmente resultam das substâncias irritantes, tóxicas e carcinogênicas provenientes da queima do cigarro, entretanto também podem estar associadas ao ressecamento da mucosa, em razão da alta temperatura intra-oral, à mudança de pH e à alteração na resposta imune (SHAM et al., 2003). Existem evidências de melhoras no quadro de saúde bucal, como cáries, recessão gengival, perda dental, perda de implantes dentários e desordens da mucosa após a interrupção do uso do cigarro em diferentes idades (SHAM et al., 2003; WARNAKULASURIYA et al., 2010; FURUKAWA et al., 2013).

Todas as alterações orais provenientes do uso do tabaco devem ser levadas em consideração, entretanto, as lesões pré-cancerosas e o câncer bucal são as mais investigadas no âmbito das pesquisas na área de patologia bucal (SHAMMARI et al., 2016). O câncer de células escamosas orais representa cerca de 90% de todos os cânceres de boca (SHAM et al., 2003). Apesar das melhorias na prevenção primária, terapia, morbidade e mortalidade, as taxas de câncer bucal permanecem altas (LI et al., 2015). A língua é um dos sítios mais acometidos pelo carcinoma de células escamosas, principalmente na região das bordas laterais e base (MOORE et al., 2000). Os tumores de língua são considerados como um dos piores sítios no que diz respeito à sobrevivência do indivíduo, isso se dá em função de sua natureza altamente invasiva, o que leva à graves alterações nas funções deste órgão (LI et al., 2015).

A língua é um órgão muscular localizado no assoalho bucal, composto de um complexo organizado de músculos estriados classificados em extrínsecos, que possuem inserção óssea e intrínsecos, que se inserem na própria língua. Os músculos extrínsecos estão associados com os movimentos de posição da língua, enquanto que os intrínsecos estão relacionados com a mudança de forma do órgão (SANDERS; MU, 2013).

A língua se destaca por possuir papel crucial na fonética, limpeza, mastigação e deglutição dos alimentos, uma vez que é responsável por misturar, controlar e impulsionar o bolo alimentar em direção à orofaringe (PARADA et al., 2012). Alterações nas funções linguais podem levar à disfagia e aos distúrbios obstrutivos do sono (SANDERS; MU, 2013).

Morfologicamente a língua se divide em três terços, o terço apical, o terço médio e o terço posterior. O terço apical compreende a região que vai do ápice lingual ao frênulo e o terço médio corresponde à região que vai do frênulo à papila circunvalada, sendo que ambos se encontram localizados na cavidade oral e são móveis. O terço posterior encontra-se posteriormente à papila circunvalada, estando localizado na faringe e é relativamente imóvel (PARADA et al., 2012; SANDERS; MU, 2013).

O complexo muscular da língua é revestido por uma superfície de epitélio escamoso estratificado queratinizado contendo em sua superfície dorsal, sensores de gustação, de dor, táteis e de temperatura (PARADA et al., 2012). Além dos tecidos glandulares, vasculares e nervosos, as células musculares estriadas intrínsecas da língua formam feixes que são separados por tecido conjuntivo e células adiposas (GARTNER et al., 1997).

As principais estruturas de tecido conjuntivo na língua são o septo médio, que é uma espessa camada de tecido conjuntivo na linha média da língua; o septo paramediano que é uma fascia que separa o músculo genioglosso do músculo inferior longitudinal e o septo lateral, que é o tecido conjuntivo que separa o músculo inferior longitudinal (SANDERS; MU, 2013)

O tecido conjuntivo lingual mantém o volume do órgão constante durante a contração muscular (SANDERS; MU, 2013). A distribuição regional das fibras colágenas é discutida em termos de compreensão da biomecânica lingual em estados normais e patológicos, por exemplo, a maior concentração de fibras na região anterior da língua é justificada por se tratar de uma região onde a resistência estrutural e a resiliência são importantes para falar e engolir (MILLER et al., 2002).

Devido às ações diretas do tabaco e seus derivados, as toxinas presentes levam à destruição do tecido conjuntivo (WEI et al., 2005). As concentrações de nicotina encontradas em fumantes passivos são capazes de aumentar a expressão da classe metaloproteinase de matriz denominada colagenase I, que leva à degradação de fibras colágenas (BARNOYA; GLANTZ, 2005).

As metaloproteinases de matriz também apresentam significativa função na progressão tumoral através do aumento da angiogênese, a qual é induzida pela presença do tumor, além de destruir a arquitetura tecidual local, permitindo assim, a invasão tumoral (KERKELÄ; SAARIALHO-KERE, U, 2003; FUN et al., 2016).

Outro componente do tecido conjuntivo lingual são os mastócitos. Primeiramente descritos apenas como células com funções efetoras nos processos inflamatórios alérgicos, os mastócitos atualmente são considerados como células imunes multifuncionais envolvidas em vários estados tanto patológicos como fisiológicos (da SILVA et al., 2014). Os mastócitos são derivados de células progenitoras hematopoiéticas que migram para tecidos vascularizados onde completam sua maturação e vivem por muito tempo. Mastócitos maturados geralmente residem próximos ao epitélio, vasos sanguíneos, nervos, células musculares e glândulas mucosas (GALLI, 2005; METCALFE, 2008).

Os mastócitos são células metacromáticas que apresentam grânulos em seu citoplasma e numerosos receptores em sua superfície. Quando estimuladas através de seus receptores, geram respostas que levam à liberação de uma variedade de mediadores biologicamente ativos, os quais são armazenados no interior de seus grânulos, esse processo é conhecido como degranulação (GALLI, 2005; da SILVA et al., 2014).

Entre os mediadores biologicamente ativos liberados, estão as proteases, proteoglicanas, citocinas, quimiocinas, fatores de crescimento, entre outros que vão desencadear diferentes funções em circunstâncias diversas, o que é influenciado pelo subtipo de mastócito e o microambiente, o qual é encontrado (GORDON, 1990; da SILVA et al., 2014). Em humanos, os mastócitos maturados são classificados em duas subcategorias de acordo com as proteases, as quais armazenam em: mastócito triptase/quimase, que armazenam quimase, triptase e carboxipeptidase A3 em seus grânulos e mastócito triptase, que armazenam apenas triptase em seus grânulos (IRANI et al., 1986; SCHWARTZ, 2006; JEONG et al., 2013). Recentemente foi descrito um terceiro subtipo de mastócito encontrado em amostras de epitélio de vias aéreas em pacientes com asma e esôfago de pacientes com esofagite eosinofílica, esses mastócitos expressam triptase e carboxipeptidase A3 e não expressam quimase (ABONIA et al., 2010; DOUGHERTY et al., 2010).

Em ratos, os mastócitos são classificados em dois subtipos baseados nas diferenças histológicas, funções, e composição, como: mastócitos de mucosa (MMC) e mastócitos de tecido

conjuntivo (CTMC). Os mastócitos de mucosa (MMC) expressam predominantemente quimases do tipo mMCP-1 e mMCP-2 e são encontrados em mucosa epitelial do trato gastrointestinal e do pulmão, enquanto que, os mastócitos de tecido conjuntivo (CTMC), expressam quimase do tipos mMCP-4, triptases do tipo mMCP-5emMCP-6, além de carboxipeptidase A e são encontrados em submucosa intestinal, cavidade peritonial, pele e língua (MATSSON, 1992; IRANI et al., 1986; JEONG et al, 2013).

Além da participação nos processos de homeostase e remodelação tecidual, os quais são bastante conhecidos, essas células também têm sido bastante citadas por possuírem importantes funções como: estabelecimento de interação neuroimune (SUZUKI, A. et al., 2004), no processo de angiogênese (CRIVELLATO et al., 2004; da SILVA et al., 2014), na resposta imune inata, adaptativa e imuno tolerância. Quando ocorre regulação inadequada de suas funções, os mastócitos podem participar também de quadros patológicos como nos casos de alergias (da SILVA et al., 2014), doença de Crohn (GELBMANN et al., 1999), doenças autoimunes (BROWN; HATFIELD, 2012), mastocitose (METCALFE, 2008), doença cardiovascular (JENNE; TSCHOPP, 1991) e câncer (da SILVA et al., 2014).

A exposição à fumaça do tabaco ativa a cascata inflamatória e mastócitos, resultando na liberação dos mediadores pró-inflamatórios, contribuindo para o prolongamento desse processo (MORTAZ et al., 2008). O processo inflamatório contribui para a diminuição do suprimento sanguíneo e conseqüentemente à níveis baixos de oxigênio, o que leva a hipóxia (TAYLOR; COLGAN, 2017). A hipóxia portanto, ocorre quando a necessidade de oxigênio de uma célula ultrapassa o fornecimento vascular e, caso esse quadro seja mantido, a hipóxia pode ser letal para as células (TAYLOR; COLGAN, 2017).

Além da inflamação, a hipóxia tecidual também pode ser provocada pela nicotina presente no cigarro, pois estimula o organismo a secretar hormônios adrenocorticais, os quais agirão promovendo contração vascular. Além disso, o monóxido de carbono contribui para a redução na saturação de oxigênio (SpO₂), uma vez que possui alta afinidade por hemácias, o que prejudica a ligação das hemácias às moléculas de oxigênio ao mesmo tempo que forma o complexo carboxihemoglobina, levando ao quadro de hipóxia (MIYANG et al., 2014; LEONE, 2015).

O fator de transcrição 1 induzido por hipóxia (HIF-1) é uma proteína básica envolvida em importantes respostas adaptativas para hipóxia, promovendo a sobrevivência celular sob essas

condições (JEONG et al., 2013). É composta de duas subunidades: HIF-1 α e HIF-1 β , sendo a subunidade α expressa na dependência da disponibilidade de oxigênio (SEMENZA et al., 2004).

Em condições de normóxia, o HIF-1 α é sintetizada, porém sofre rápida degradação por hidroxilases, contudo, quando a disponibilidade de oxigênio é reduzida, as hidroxilases são inibidas e conseqüentemente a degradação do HIF-1 α não ocorre, permanecendo assim, estável no citoplasma. O acúmulo de HIF-1 α no citoplasma permite sua translocação para o núcleo, onde se une com a subunidade β . A subunidade α e β formam juntas o fator de transcrição HIF-1, os quais ativam a transcrição de genes como: eritropoietina (EPO), responsável por regular a eritropoiese e importante determinante da capacidade de transporte de oxigênio no sangue; o fator de crescimento endotelial vascular (VEGF), primeiro regulador de angiogênese; enzimas glicolíticas como aldolase A (ALDA), enolase 1 (ENO1), lactato desidrogenase A (LDHA), fosfofructoquinase L (PFKL), fosfogliceratoquinase 1 (PGK1), os quais fornecem um atalho metabólico para a geração de ATP na ausência de oxigênio, entre outros (SEMENZA et al., 2004; BERCHNER-PFANNSCHMIDT et al., 2008; TAYLOR; COLGAN, 2017).

Estudos anteriores relataram que a fumaça do cigarro induz a ativação de HIF-1 α , o qual vai regular a expressão de níveis de VEGF, REDD1, MMP-9 e HO-1, os quais estão envolvidos na doença pulmonar obstrutiva crônica (YU et al., 2012; DAIJO et al., 2016). Outros estudos demonstraram que no microambiente tumoral, a histamina liberada através da degranulação de mastócitos induz a expressão de HIF-1 α que por sua vez, induz a migração de mais mastócitos através da produção de VEGF (JEONG et al., 2013).

Alguns estudos semelhantes avaliaram língua de ratos expostos à fumaça do tabaco e encontraram alterações como desordens nas papilas filiformes (MARTINS et al., 2014), superexpressão de bcl-2, um proto-oncogene e inibidor de apoptose, em queratinócitos da língua, tornando-os passíveis de mutações e conseqüentemente, de progressões tumorais (ASSIS et al., 2005). Outro estudo realizado também na língua de ratos demonstrou hiperplasia epitelial, aumento da camada de queratina e displasia média na mucosa lingual, além de evidente expressão positiva de ki-67, um importante marcador de proliferação celular, usado para avaliar frações de crescimento em neoplasias humanas (de OLIVEIRA SEMENZATI et al., 2012).

Embora alguns autores já demonstraram alterações epiteliais das línguas de ratos expostos à fumaça do tabaco (ASSIS et al., 2005; MARTINS et al., 2014), não foram encontrados estudos que descreveram alterações no tecido conjuntivo lingual frente à inalação passiva do tabaco.

Dessa forma, levantamos a hipótese de que não somente o epitélio, mas o tecido conjuntivo lingual também poderia sofrer alterações teciduais decorrentes da fumaça lateral do cigarro. Sabendo da importância da língua na deglutição, mastigação e fala, justifica-se a realização do presente estudo que teve como objetivo realizar avaliação histopatológica do epitélio e da musculatura das línguas de ratos expostos à fumaça lateral do cigarro.

Capítulo I: artigo submetido à revista *Inhalation Toxicology*

Histopathological analysis of the epithelial tissue and tongue musculature of rats submitted to inhalation of tobacco smoke

Eleonora de Paula Amaral^a, Rodrigo César Rosa^b, Renata Margarida Etchebehere^c, Ruchele Dias Nogueira^a, José Batista Volpon^d, Denise Bertulucci Rocha Rodrigues^{a,e}, Sanívia Aparecida de Lima Pereira^{a,e*}

^a *Laboratory of Cellular and Molecular Biology, University of Uberaba, Brazil*

^b *Department of Structural Biology of the Institute of Biological and Natural Sciences of Federal University of the Triângulo Mineiro, Uberaba, Brazil.*

^c *Hospital of Clinics, Service of Surgical Pathology, Federal University of the Triângulo Mineiro, Uberaba, Brazil.*

^d *Department of Biomechanics, Medicine and Rehabilitation of Locomotive Apparatus, University of São Paulo, Ribeirão Preto, Brazil.*

^e *Cefores, Federal University of the Triângulo Mineiro, Uberaba, Brazil.*

**Corresponding author at: Universidade de Uberaba, Av. Nenê Sabino, 1801, Bairro Universitário. CEP 38.055-500, Uberaba, MG, Brazil*

Tel.: +55 34 3319 8815

Fax: +55 34 3314 8910

E-mail address: sanivia.pereira@uniube.br (S.A. de Lima Pereira)

Abstract:

Introduction: Smoking is a risk factor for serious health problems that can also affect passive smokers. Furthermore, it is associated with several changes in the tissues of the oral cavity.

Objective: To evaluate the presence of epithelial dysplasia and inflammation, collagen percentage, mast cells density and intensity of immunolabelled cells to anti-HIF-1 α in the rats tongue musculature. **Methods:** Twenty seven female Wistar albino rats were divided into three

groups: rats not exposed to tobacco smoke inhalation (Control group) (n = 7); rats exposed to smoke inhalation for 30 days (TAB 30) (n = 10); and rats exposed to inhalation of tobacco smoke for 45 days (TAB 45) (n = 10). Subsequently, the animals were submitted to euthanasia with subsequent removal of the tongue for histological and immunohistochemistry processing.

Results: In the groups exposed to cigarette smoke, a lower percentage of collagen, a higher density of mast cells and a greater intensity of anti-HIF-1 α immunolabelled cells were observed.

There was also a positive and significant correlation between the percentage of collagen and mast cell density. **Conclusion:** Exposure of rats to smoke of tobacco causes decrease in perimysial collagen fibers, increase in the number of mast cells, and increase in immunostaining for HIF-1 α in lingual muscle cells. Knowing the importance of lingual musculature in swallowing, chewing and speaking, new studies should be carried out to better understand the pathogenesis of lingual changes in passive inhalation of tobacco smoke.

Keywords: passive smoker, rats, second hand smoke, tobacco, tongue.

Introduction

Smoking is the major modifiable risk factor associated with severe health problems such as cancer, cardiovascular disorders, respiratory diseases, infertility and one of the leading causes of preventable death (Colombo et al., 2014). Cigarette smoke contains approximately 5600 constituents (Perfetti and Rodgman 2011), of which at least 158 present carcinogenic or toxic properties (Fowles and Dybing 2003; Thorne and Adamson 2013). Thus, passive smoking also increases the risk of developing diseases caused by the toxins of cigarette components (Behera et al., 2014), and accounts for 10% of tobacco-related deaths in these individuals (WHO / Tobacco 2015).

Smoking and exposure to tobacco smoke are important risk factors for several changes in the oral mucosa, such as neoplasia and epithelial dysplasia (Reibel 2003). Oral epithelial dysplasia is histopathologically characterized by cellular and structure alterations of the lining epithelium (Jaber 2010). Only one study that demonstrated dysplasia in the lingual epithelium of rats exposed to tobacco smoke was found (de Oliveira Semenzati et al., 2012).

In addition to the epithelium, the toxic substances of tobacco lead to the destruction of collagen fibers in the connective tissue (Wei et al., 2005), by increasing the expression of metalloproteinases (Carty CS et al., 1996; Barnoya and Glantz 2005). Connective tissue mast cells also suffer from the action of tobacco toxic substances, such as acrolein, which promotes mastocyte degranulation with a consequent inflammatory reaction (Hochman et al., 2008). In addition, exposure to long-term tobacco smoke increases the number of mast cells that produce important growth factors in angiogenesis (Kispert et al., 2017) and fibrosis (da Silva et al., 2014).

Tissue hypoxia, induced by smoking and exposure to tobacco smoke, can also cause tissue damage (Taylor and Colgan 2017). Hypoxia in these cases can be triggered by the action of nicotine which stimulates the secretion of adrenocortical hormones that promote vascular contraction and reduction of local blood flow (Miyang et al., 2014). Additionally, carbon monoxide contributes to the reduction in oxygen saturation (SpO₂) and the formation of carboxyhemoglobin which also contributes in tissue hypoxia (Miyang et al., 2014; Leone 2015).

One way to assess whether the tissue is in hypoxia is to investigate the presence of hypoxia-induced transcription factor 1 (HIF-1) (Semenza 2004). HIF-1 is a heterodimeric protein composed of two subunits: HIF-1 α and HIF-1 β , the α subunit being expressed in dependence on

the availability of oxygen (Semenza 2004). In hypoxia conditions the HIF-1 complex translocates to the nucleus and induces the transcription of genes related to hypoxia-adaptive mechanisms such as angiogenesis, oxygen transport, generation of ATP in the absence of oxygen, apoptosis and metastasis (Semenza 2004), which will assist in cell survival under these conditions (Jeong et al., 2013).

Although some authors have shown epithelial changes in the tongues of rats exposed to tobacco smoke (Assis et al., 2005; Martins et al., 2004), no studies have been found to describe changes in the lingual musculature due to passive inhalation of tobacco. Thus, we hypothesized that not only the epithelium, but also the lingual musculature could present tissue alterations resulting from side stream smoke. Knowing the importance of tongues in swallowing, chewing and speaking, it is justified to carry out the present study that aimed to perform histopathological evaluation of the epithelium and musculature of the tongues of rats exposed to side stream smoke.

Methods

The present study was elaborated according to the Guide for Care and Use of Laboratory Animals (NRC 2011) and approved by the Ethics Committee on Animal Use of the University of Uberaba (CEUA), protocol n° 070/2017 (Annex I).

Animals and groups

Twenty-seven female albino rats (*Rattus norvegicus*) of the Wistar lineage, with a mean initial body mass of 150 g (\pm 10 g) supplied by the Biotério Central of the City Hall of Ribeirão Preto Campus of the University of São Paulo were used. The sample calculation was performed considering the loss rate of approximately 30% (Santiago et al., 2017).

The animals were housed in standard cages at the Bioengineering Laboratory of the Medical School of Ribeirão Preto (FMRP / USP), where they remained during the whole experimental period under ambient temperature of 20° C to 24° C, with light cycles of 12 hours

clear and 12 hours dark, with relative air humidity at 55% ($\pm 10\%$) and without restriction to food or water.

The animals were randomly assigned to three experimental groups: female rats not exposed to the inhalation of tobacco smoke (control group) ($n = 7$); female rats exposed to smoke inhalation for 30 days (TAB 30) ($n = 10$); and female rats exposed to inhalation of tobacco smoke for 45 days (TAB 45) ($n = 10$).

Exposure of rats to tobacco smoke

The exposure of rats to tobacco smoke was performed according to methods previously described (Wang et al., 1999; Gentner and Weber 2012, Santiago et al., 2017).

The animals were placed inside a rectangular acrylic box composed by four cylindrical transparent acrylic tubes. In each tube was placed an animal. Each tube has one end with a controllable physical restrictor to prevent the animals from retreating and another tapered end that connects with a container that distributes the smoke interspersed with ambient air to the four tubes. The cigarette smoke "puffs" inside the box were removed by suction through a peristaltic pump (Provitec - model: AWG 5,000 AX-D), which has a timer that controls the time of injection of ambient air or smoke within the tubes in 30 second cycles of exposure to ambient air and 15 seconds of exposure to smoke. All equipment, except the pump, was placed inside the transparent acrylic box, connected to an exhaust hood that promotes the cleaning of ambient air. Four animals were simultaneously exposed to cigarette smoke (Annex II, figure 1).

The cigarette used was Marlboro (Phillips Morris), with each unit containing: 0.8 mg of nicotine, 10 mg of tar and 10 mg of carbon monoxide (values measured by Laboratory Labstat - Canada, according to product label).

The animals went through the set-up phase in the equipment for a period of 20 minutes without smoke, twice a day, with six- hour interval, in the morning and afternoon for seven consecutive days. The 20 minutes corresponded to the time of exposure to two cigarettes (cycles of 30 seconds of exposure to ambient air and 15 seconds of exposure to smoke).

Later, the animals were submitted to adaptation to tobacco smoke for seven consecutive days by burning a cigarette twice a day (morning and afternoon), with a six-hour interval between exposures. After the adaptation period, the rats were exposed to the smoke of two cigarettes in

the morning and two more cigarettes in the afternoon, with a 6 hour interval, for 30 or 45 days according to the experimental groups. In order to guarantee similar exposure to tobacco smoke, once every seven days the percentage of carbon monoxide in each camera of the equipment was measured using a portable carbon monoxide meter (Instrutemp ITMCO-1500, SP, and Brazil)

Evaluation of weight, euthanasia and blood sampling

The animals were weighed weekly with a semi-analytical balance (Digital Electronic Scale from 0 to 3kg, TOLEDO, mod. 9094) with a capacity of up to 5200g, with 0.1g precision resolution.

At the end of the experiment the animals were submitted to euthanasia with excessive dose (3mL/100g) of Thiopental (sodium thiopentate, 1.25% solution) administered intraperitoneally. Then the blood samples were collected by means of open cardiac puncture and kept in boxes with ice. Subsequently, within two hours after the collection, these samples were centrifuged for separation of the plasma using a centrifuge (HETTICH, mod. EBA 280). Soon after, the plasma was stored at -20° C until plasma cotinine was assessed in order to verify if plasma cotinine levels were the same as those found in passive smokers.

Dosage of cotinine

Plasma cotinine dosage was performed by means of gas chromatography analysis, according to the routine methodology of the Laboratory of Forensic Toxicological Analysis of the Faculty of Philosophy, Sciences and Letters of Ribeirão Preto (FFCLRP / USP). Standard: cotinine in 1.0 mg / mL solution in methanol (Sigma-AldrichTM - Missouri, USA). Gas chromatography has specificity of 97.4% and sensitivity of 96.3%. To be considered as a passive smoker, plasma cotinine levels should be between 2.1 and 17.5 ng / mL (Connor et al., 2009).

After the dosage of cotinine, the heads of animals were placed in 10% formaldehyde and then transported to the Human Anatomy Laboratory of the Department of Structural Biology of the Federal University of Triângulo Mineiro (DBE / UFTM), where the fragments of tongues were collected.

Collection of tongues samples, histochemical and immunohistochemical processing

The tongue were collected by means of a medial incision in the region of the retromolar trigone and anterior region of the neck, followed by avulsion of the skin, resection of the musculature of the floor of the mouth and disarticulation of the temporomandibular joint. An incision was made in the region of the epiglottic vallecula with removal of the tongue and mandible, which were fixed in 10% formaldehyde for later lingual resection.

Fragments of the tongue were then collected by a longitudinal cut along the medial lingual groove, from the base to the apex. These fragments were processed histopathologically obtaining 5- μ m-thick sections. Then, the fragments were stained with Hematoxylin and Eosin for histopathological evaluation of epithelial dysplasia and inflammation; with Toluidine blue for determination of mast cell density; and Picrosirius for quantification of collagen percentage. Additional sections were used for immunohistochemical processing for HIF-1 α .

Analysis of dysplasia and inflammation

The analysis of dysplasia and inflammation was performed using a light microscope (Nikon Eclipse 80i) and a 40x objective lens. The analyses were performed separately in the apical, middle and posterior thirds.

A semi-quantitative evaluation of the intensity of epithelial dysplasia and inflammatory infiltrate in the different thirds of the tongue was performed in all fields, using the following scores: 0 - absent or 1 - present (Semberova et al., 2013).

Determination of the percentage of collagen

For morphometric quantification of collagen, picrosirius-stained slides were analyzed on a standard Axio 4.1 light microscope (Zeiss, Berlin, Germany) using a 20x objective and a polarizing filter. The analyses were performed separately in the apical, middle and posterior thirds. All fields of the slides containing muscle tissue were transmitted to the computer monitor with the aid of an Axiocam image capture camera (Zeiss, Berlin, Germany). Axiovision 4.8 software (Zeiss, Berlin, Germany) was used for morphometric analysis of the collagen

percentage. In the polarized image the collagen presented birefringence with yellowish, reddish or greenish coloration, being quantified semi-automatically (Figures 2A and 2B).

Determination of mast cell density

To determine the mast cell density, the blades stained by toluidine blue were analyzed using the 40x objective. The analyses were performed separately in the apical, middle and posterior thirds. With the aid of a micrometer blade, the area of each field (0.14 mm²) was calculated, being multiplied by the total number of fields analyzed to obtain the total area. With the total number of mast cells and the total area analyzed, the mast cell density was calculated and expressed in mast cells per μm^2 .

Immunohistochemical processing and analysis of anti-HIF-1 α -immunolabelled cells:

The anti-HIF-1 α mouse monoclonal antibody (Sigma-Aldrich, dilution 1: 500, Saint Louis, MO, USA) diluted in bovine serum albumin dissolved in PBS (Sigma-Aldrich, Missouri, USA) was used for the immunohistochemical reaction, according to the manufacturer's instructions. For detection of the antibody, the polymer detection system (Spring, Pleasanton, CA, USA) was used as a biotin-free system. The immunohistochemical reaction of each antibody was visualized using chromogenic diaminobenzidine-DAB solution (Sigma Chemical CO, Missouri, USA).

The immunohistochemical evaluation of the immunomarker cells was performed semi-quantitatively using a microscope (Nikon Eclipse 80i) and a 40x objective. For this evaluation, the following scores were used: 1 - weak expression (up to 33% of the immunolabelled cells), 2 - strong expression (> 33% of the immunolabelled cells) (de Araújo et al. 2017).

Statistical analysis

The statistical analyses were performed using GraphPad Prism 5.0 and Bioestat 5.0 software. For the evaluation of the final weight of the animals, cotinine dosage and mast cell

density, ANOVA and Tukey post-test were used, since the data presented normal distribution. However, for the evaluation of the collagen percentage and the immunostaining for HIF-1 α , the Kruskal-Wallis tests and the Dunn post-test were applied, since the data presented a non-normal distribution. To correlate the mast cell density and collagen percentage, the Pearson correlation test was used for the data that presented normal distribution and the Spearman correlation test for data that presented a non-normal distribution. All analyses were performed assuming a significance level of 5%.

Results

During the adaptation period, approximately 8% of the animals were lost, being two animals in TAB- 45 group.

The mean levels of carbon monoxide were similar at all measurements (338.79 ± 1.16 ppm). Animals from all groups presented significant weight gain when comparing initial body weight and final body weight ($p < 0.0001$). When the final weight of the animals was compared between the groups, it was observed that the groups exposed to tobacco had significantly lower final weight in relation to the control group (Figure 3).

The mean values and standard deviation of the cotinine dosage were: control group (0.005 ± 0.009); TAB 30 (7.66 ± 0.96) and TAB 45 (9.13 ± 0.95). Thus, mean cotinine levels were significantly higher in the groups exposed to smoke than in the control group, and the TAB 45 group had higher cotinine levels when compared to the TAB 30 group ($p < 0.0001$).

No epithelial dysplasia was observed in any of the analyzed cases (Figure 4A). Chronic inflammation was observed in the apical third of the tongue of two cases, one animal of control group and one animal of TAB 45 group (Figure 4B).

The percentage of collagen in the apical and posterior third of the tongue was significantly lower in the TAB 30 and TAB 45 groups than in the control group ($p < 0.0001$). In the middle third, there was no significant difference between the groups in relation to the percentage of collagen (Figure 5).

The mast cell density was significantly higher in TAB 30 and TAB 45 groups than in the control group, observed in the apical third ($p = 0.0608$), in the middle third ($p = 0.0163$) as well

as in the posterior third of the tongue ($p = 0.0007$) (Figure 6 and 7).

There was a positive and significant correlation between collagen percentage and mast cell density when evaluating the tongue as a whole, both in TAB 30 and TAB 45 groups ($p < 0.0001$). However, there was no significant correlation when the three thirds were evaluated singly (Figure 8A and 8B).

Immunostaining for HIF-1 α was observed only in the lingual muscle cells and was significantly higher in the TAB 45 group than in the control group: in the apical third ($p = 0.0036$), in the middle third ($p = 0.0029$), and in the posterior third ($p = 0.0007$). TAB 30 group showed significantly higher immunostaining for HIF-1 α than the control group only in the posterior third of the tongue ($p = 0.0007$) (Figure 9 and 10).

No significant correlation was observed between mast cell density and immunolabelled intensity for HIF-1 α (data not shown).

Discussion

The present study was the first to evaluate the percentage of collagen, mast cell density and immunolabelled for HIF-1 α in rat tongues exposed to secondary tobacco smoke.

The loss of 8% of the animals was probably due to intoxication from tobacco smoke, which was already foreseen in the exposure protocol (Santiago et al., 2017).

Although animals of all groups showed weight gain, the final weight of the animals in the groups exposed to tobacco was significantly lower in comparison to the final weight of the control group animals. This finding corroborates another study that also observed lower body weight in rats exposed to secondary tobacco smoke (Chaichalotornkul et al., 2015). The decrease in weight gain in animals exposed to cigarette smoke may have been caused by the action of nicotine in the smoke that leads to reduced appetite and altered eating patterns, as already demonstrated in other studies (Jo et al., 2002; Chaichalotornkul et al., 2015).

Epithelial dysplasia has been described in the tongue and pharynx of rats exposed to smoke (de Oliveira Semenzati et al., 2012). However, we did not find any cases with dysplasia in the present study, perhaps due to the amount of cigarettes and the time of exposure, which may not have been enough to cause this alteration. In addition, only two cases of chronic inflammation

were observed. Since this inflammation was present in the apical third, we believe that this process is a result of bite trauma.

Although we have not found studies that evaluated the percentage of collagen in the tongues of both humans and animals exposed to tobacco smoke, some authors have already shown an increase in the amount of collagen in the salivary glands (Ferragut et al., 2011) and in mammary tissue (Kispert et al., 2017) from rats and in the heart of hamsters (Wu et al., 2014) as a consequence of passive inhalation of tobacco. In the present study, the percentage of collagen in the apical third and the posterior third of the tongue was significantly lower in TAB 30 and TAB 45 groups than in the control group. Our findings corroborate with other studies that also found a reduction in the amount of collagen in the lungs of mice (Valença and Porto 2008) and in the skin of Wistar rats (Chaichalotornkul et al., 2015) exposed to cigarette smoke.

The reduction in the percentage of collagen in the tongue of rats exposed to tobacco smoke may have been caused by nicotine and cotinine, leading to an increase in the expression of metalloproteinases, such as collagenases (Barnoya and Glantz 2005; Kispert et al., 2017), that induce the destruction of collagen fibers type I, II and III (Kerkelä and Saarialho-Kere 2003). Moreover, the inhalation of tobacco smoke leads to an increase in the production of reactive oxygen species, such as superoxide (Barnoya and Glantz 2005; Domej et al., 2006; Barbosa et al., 2010) and reactive nitrogen species, such as nitric oxide (Domej et al., 2006), which also cause destruction of the extracellular matrix (Domej et al., 2006; Valença and Porto 2008).

As there was a lower percentage of collagen found only in the apical third and the posterior third of TAB 30 and TAB 45 groups, we believe that these regions would be more exposed to the action of tobacco smoke. This is because during exposure to smoke, animals constantly open their mouths, which allows greater contact of the smoke with the apical third of the tongue. In addition, during inhalation the smoke penetrates the nasal region and passes through the oropharynx directly reaching the posterior region of the tongue, which could also justify the lower percentage of collagen in this region.

Studies have shown that there is an increase in the number of mast cells in the ducts and lymph nodes of mammary tissue (Kispert et al., 2017) and in the airways (Mortaz et al., 2012) of rats exposed to tobacco smoke. These findings corroborate with the present study because we found significantly higher mast cell density in the apical, middle and posterior thirds of TAB 30 and TAB 45 groups in relation to the control group.

Mast cells are metachromatic cells that display granules in their cytoplasm and numerous surface receptors (Galli et al., 2005, da Silva et al., 2014), which when stimulated release biologically active mediators such as proteases, proteoglycans, cytokines, chemokines and growth factors (da Silva et al., 2014). As already described, resident mast cells of the airways are exposed to side stream smoke (Mortaz et al., 2012). Furthermore, it is known that toxic substances present in tobacco smoke, such as acrolein, cause mast cell degranulation (Hochman et al., 2008) and that some substances released during this degranulation cause recruitment of progenitor mast cells to the tissue, where they are finally matured (Collington et al., 2011). Thus, the increase in mast cell density in the groups exposed to tobacco smoke in the present study may have occurred as a result of chemical mediators released by these cells, which would be participating in the recruitment of progenitor mast cells from the bone marrow, contributing to the increase of mast tissue population in the lingual tissue.

Mast cells have been prominent because they are involved in several physiological and pathological processes, but one of the most well-known functions of these cells is the participation in the process of collagen synthesis through fibroblastic activation (da Silva et al., 2014). Studies have shown a positive correlation between fibrosis and mast cell density in tongue of chronic chagasic patients (de Lima Pereira et al., 2007) and atherosclerotic aortas (Ramalho et al., 2013) of necropsied patients. These studies corroborate our findings because we observed a positive and significant correlation between the percentage of collagen and the density of mast cells in the tongue. Thus, in the present study, the passive inhalation of tobacco smoke would be causing an increase in number and mast cell degranulation with consequent release of fibrogenic factors. However, as there was a lower percentage of collagen in the groups exposed to tobacco smoke when compared to control group, we believe that the collagen destruction caused by the action of the smoke is overcoming the deposition process.

HIF-1 is a basic protein composed of two subunits: HIF-1 α and HIF-1 β . The α subunit is expressed in dependence on the availability of oxygen. This protein is involved in important adaptive responses to hypoxia, promoting cell survival under these conditions (Semenza 2004). Although studies have reported a decrease in HIF-1 α in lung tissue of adult rats (Wagner et al., 2015) and progeny of rats (Singh et al., 2015) exposed to tobacco smoke, our findings demonstrated that the immunolabeling anti-HIF-1 α was significantly higher in the TAB 45 groups when compared to the control group, in the three thirds analyzed. In the posterior third,

TAB 30 group presented significantly higher anti-HIF-1 α immunolabeling than the control group. Our findings corroborate other studies that also found an increase in HIF-1 α levels in cultures of human lung cancer cells exposed to nicotine (Zhang et al., 2007), in the nasal tissue of rat models with eosinophilic rhinosinusitis exposed to the smoke of tobacco (Lee et al., 2004) and in orbital fibroblasts exposed to tobacco smoke extract (Görtzg et al., 2016).

In the present study, the increase in HIF-1 α expression in the groups exposed to tobacco smoke probably occurred due to the action of nicotine and carbon monoxide present in the smoke, which would cause both vasoconstriction (Miyang et al., 2014) and complex formation carboxyhemoglobin, which prevent the binding of the oxygen molecule to hemoglobin, difficulting the transport and supply oxygen to the cells (Miyang et al., 2014; Leone 2015). As TAB 45 group showed the highest immunolabeling for HIF-1 α in relation to the control group in the three thirds analyzed, we believe that tissue hypoxia occurs with a longer exposure to tobacco smoke. However, as the posterior third of TAB 30 group also presented greater immunolabeling for HIF-1 α when compared to the control group, we believe that this region was more exposed to the local action of the smoke inhalation.

Therefore, the exposure of rats to cigarette smoke causes decrease in perimysial collagen fibers, increase in the number of mast cells and increase in immunolabeling for HIF-1 α in lingual muscle cells. Knowing the importance of lingual musculature in swallowing, chewing and speaking, new studies should be carried out to better understand the pathogenesis of lingual changes in passive inhalation of tobacco smoke.

Acknowledgments

Programa de Pós Graduação em Odontologia da Universidade de Uberaba (UNIUBE); Cefores da Universidade Federal do Triângulo Mineiro (UFTM); Conselho Nacional de Desenvolvimento Científico e Tecnológico (CNPq); Coordenação de Aperfeiçoamento de Pessoal de Nível Superior (CAPES); Fundação de Amparo à Pesquisa do Estado de Minas Gerais (FAPEMIG).

Declaration of conflict of interest

There is no conflict of interest to declare.

References

- Assis GF, Ceolin DS, Marques ME, Salvadori DM, Ribeiro DA. 2005. Cigarette smoke affects apoptosis in rat tongue mucosa: role of bcl-2 gene family. *J Mol Histol* 36:483-9.
- Barbosa KB, Costa NM, Alfenas RC, de Paula SO, Minim VP, Bressan J. 2010. Oxidative stress: concept, implications and modulating factors. *Rev Nutr* 23:629-643.
- Barnoya J, Glantz SA. 2005. Cardiovascular effects of secondhand smoke: nearly as large as smoking. *Circulation* 111:2684–2698.
- Behera SN, Xian H, Balasubramanian R. 2014. Human health risk associated with exposure to toxic elements in mainstream and sidestream cigarette smoke. *Sci Total Environ* 15:947-56.
- Carty CS, Soloway PD, Kayastha S, Bauer J, Marsan B, Ricotta JJ, Dryjski M. 1996. Nicotine and cotinine stimulate secretion of basic fibroblast growth factor and affect expression of matrix metalloproteinases in cultured human smooth muscle cells. *J Vasc Surg* 24:927-34.
- Chaichalotornkul S, Nararatwanchai T, Narkpinit S, Dararat P, Kikuchi K, Maruyama I, Tancharoen S. 2015. Secondhand smoke exposure-induced nucleocytoplasmic shuttling of HMGB1 in a rat premature skin aging model. *Biochem Biophys Res Commun* 456:92-7.
- Collington SJ, Williams TJ, Weller CL. 2011. Mechanisms underlying the localisation of mast cells in tissues. *Trends Immunol* 32:478-85.
- Colombo G, Clerici M, Giustarini D, Portinaro NM, Aldini G, Rossi R, Milzani A, Dalle-Donne I. 2014. Pathophysiology of tobacco smoke exposure: recent insights from comparative and redox proteomics. *Mass Spectrom Rev* 33:183-218.

Connor GS, Schofield-Hurwitz S, Hardt J, Levasseur G, Tremblay M. 2009. The accuracy of self-reported smoking: a systematic review of the relationship between self-reported and cotinine-assessed smoking status. *Nicotine Tob Res* 11:12-24.

da Silva EZ; Jamur MC; Oliver C. 2014. Mast cell function: a new vision of an old cell. *J Histochem Cytochem* 62:698-738.

de Araújo MF; Etchebehere RM; de Melo MLR; Beghini M; Severino VO; de Castro Cobo E; Rocha Rodrigues DB; de Lima Pereira SA. 2017. Analysis of CD15, CD57 and HIF-1 α in biopsies of patients with peri-implantitis. *Pathol Res Pract* 213:1097-1101.

de Lima Pereira SA, dos Santos VM, Rodrigues DB, da Cunha Castro EC, dos Reis MA, de Paula Antunes Teixeira V. 2007. Quantitative analysis of fibrosis and mast cells in the tongue of chronic chagasic patients: autopsy study. *Med Mal Infect* 37:229-33.

de Oliveira Semenzati G, de Souza Salgado B, Rocha NS, Michelin Matheus SM, de Carvalho LR, Garcia Martins RH. 2012. Histological and immunohistochemical study of the expression of p53 and ki-67 proteins in the mucosa of the tongue, pharynx and larynx of rats exposed to cigarette smoke. *InhalToxicol* 24:723-31.

Domej W, Földes-Papp Z, Flögel E, Haditsch B. 2006. Chronic obstructive pulmonary disease and oxidative stress. *Curr Pharm Biotechnol* 7:117-23.

Ferragut JM, da Cunha MR, Carvalho CA, Isayama RN, Caldeira EJ. 2011. Epithelial-stromal interactions in salivary glands of rats exposed to chronic passive smoking. *Arch Oral Biol* 56:580-7.

Fowles J, Dybing E. 2003. Application of toxicological risk assessment principles to the chemical constituents of cigarette smoke. *Tob Control* 12:424-30.

Galli SJ, Kalesnikoff J, Grimbaldston MA, Piliponsky AM, Williams CM, Tsai M. 2005. Mast cells as "tunable" effector and immunoregulatory cells: recent advances. *Annu Rev Immunol* 23:749-86.

Gentner NJ, Weber LP. 2012. Secondhand tobacco smoke, arterial stiffness, and altered circadian blood pressure patterns are associated with lung inflammation and oxidative stress in rats. *Am J Physiol Heart Circ Physiol* 302:H818-25.

Görtz GE, Horstmann M, Aniol B, Reyes BD, Fandrey J, Eckstein A, Berchner-Pfannschmidt U. 2016. Hypoxia-Dependent HIF-1 Activation Impacts on Tissue Remodeling in Graves' Ophthalmopathy-Implications for Smoking. *J Clin Endocrinol Metab* 101:4834-4842.

Hochman DJ, Collaco CR, Brooks EG. 2008. Acrolein induction of oxidative stress and degranulation in mast cells. *Environ Toxicol* 29:908-15.

Jaber MA. 2010. Tobacco smoking and alcohol consumption as risk factors for site-specific intra oral epithelial dysplasia. *J Investig Clin Dent*, 1:101-7.

Jeong HJ, Oh HA, Nam SY, Han NR, Kim YS, Kim JH, Lee SJ, Kim MH, Moon PD, Kim HM, et al. 2013. The critical role of mast cell-derived hypoxia-inducible factor-1a in human and mice melanoma growth. *Int J Cancer* 132:2492-2501.

Jo YH, Talmage DA, Role LW. 2002. Nicotinic receptor-mediated effects on appetite and food intake. *J Neurobiol* 53:618-32.

Kerkelä E, Saarialho-Kere U. 2003. Matrix metalloproteinases in tumor progression: focus on basal and squamous cell skin cancer. *Experimental Dermatology* 12:109-125.

Kispert S, Crawford S, Kolar G, Mchowat J. 2017. In Vivo Effects of Long-Term Cigarette Smoke Exposure on Mammary Tissue in Mice. *Am J Pathol* 187:1238-1244.

Lee KI, Kim DW, Kim EH, Kim JH, Samivel R, Kwon JE, Ahn JC, Chung YJ, Mo JH. 2014. Cigarette smoke promotes eosinophilic inflammation, airway remodeling, and nasal polyps in a murine polyp model. *Am J Rhinol Allergy* 28:208-14.

Leone A. 2015. Toxics of Tobacco Smoke and Cardiovascular System: From Functional to Cellular Damage. *CurrPharm Des* 21:4370-9.

Martins RH, Goncalves TM, Madeira SL, Dias NH, de Oliveira Semenzati G. 2014. Scanning electron microscopy of the tongue, pharynx, and larynx of rats exposed to cigarette smoke. *J Voice* 28:287-90.

Miyang J, Hyeoncheol J, Lee K, Yim J. 2014. The acute effect of smoking a single cigarette on vascular status, SpO₂, and stress level. *Med Sci Monit* 20: 601-7.

Mortaz E, Givi ME, da Silva CA, Folkerts G, Redegeld FA. 2012. A relation between TGF- β and mast cell tryptase in experimental emphysema models. *Biochim Biophys Acta* 1822:1154-60.

National Research Council (NRC). 2011. *Guide for the Care and Use of Laboratory Animals: Eighth Edition*. Washington, DC: The National Academies Press.

Perfetti TA, Rodgman A. 2011. The Complexity of Tobacco and Tobacco Smoke. *The Journal of BTFI GmbH* 24:12-30.

Ramalho LS, Oliveira LF, Cavellani CL, Ferraz ML, de Oliveira FA, Miranda Corrêa RR, de Paula Antunes Teixeira V, de Lima Pereira SA. 2013. Role of mast cell chymase and tryptase in the progression of atherosclerosis: study in 44 autopsied cases. *Ann Diagn Pathol* 17:28-31.

Reibel J. 2003. Tobacco and oral diseases. update on the evidence with recommendations. *Med Princ Pract* 12: 22-32.

Santiago HA, Zamarioli A, Sousa Neto MD, Volpon JB. 2017. Exposure to Secondhand Smoke Impairs Fracture Healing in Rats. *Clin Orthop Relat Res* 475:894-902.

Semberova J, Rychly B, Hanzelova J, Jakubikova J. 2013. The immune status in situ of recurrent tonsillitis and idiopathic tonsillar hypertrophy. *Bratisl Lek Listy* 114:140-4.

Semenza GL. 2004. Hydroxylation of HIF-1: oxygen sensing at the molecular level. *Physiology (Bethesda)* 19:176-82.

Singh SP, Chand HS, Gundavarapu S, Saeed AI, Langley RJ, Tesfaigzi Y, Mishra NC, Sopori ML. 2015. HIF-1 α Plays a Critical Role in the Gestational Sidestream Smoke-Induced Bronchopulmonary Dysplasia in Mice. *PLoS One* 10:e0137757.

Taylor CT, Colgan SP. 2017 Oct. Regulation of immunity and inflammation by hypoxia in immunological niches. *Nat Rev Immunol*.

Thorne D, Adamson J. 2013. A review of in vitro cigarette smoke exposure systems. *Exp Toxicol Pathol* 65:1183-93.

Valença SS, PortO LC. 2008. Immunohistochemical study of lung remodeling in mice exposed to cigarette smoke. *J Bras Pneumol* 34:787-95.

Wagner K, Gröger M, Mccook O, Scheuerle A, Asfar P, Stahl B, Huber-Lang M, Ignatius A, Jung B, Duechs M, et al. 2015. Blunt Chest Trauma in Mice after Cigarette Smoke-Exposure: Effects of Mechanical Ventilation with 100% O₂. *PLoS One* 10:e0132810.

Wang XD, Liu C, Bronson RT, Smith DE, Krinsky NI, Russel M. 1999. Retinoid signaling and activator protein-1 expression in ferrets given beta-carotene supplements and exposed to tobacco smoke. *J Natl Cancer Inst* 91:60-6.

Wei XM, Kim HS, Kumar RK, Heywood GJ, Hunt JE, Mcneil HP, Thomas PS. 2005. Effects of cigarette smoke on degranulation and NO production by mast cells and epithelial cells. *Respir Res* 19:108.

World Health Organization (WHO). 2015. Tobacco: relatório n° 339 de julho de 2015.

Wu JP, Hsieh CH, Ho TJ, Kuo WW, Yeh YL, Lin CC, Kuo CH, Huang CY. 2014. Secondhand smoke exposure toxicity accelerates age-related cardiac disease in old hamsters. *BMC Cardiovasc Disord* 14:195.

Zhang Q, Tang X, Zhang ZF, Velikina R, Shi S, Le AD. 2007. Nicotine induces hypoxia-inducible factor-1alpha expression in human lung cancer cells via nicotinic acetylcholine receptor-mediated signaling pathways. *Clin Cancer Res* 13:4686-94.

Conclusão

Conclusão

Portanto, a exposição de ratos à fumaça do cigarro provoca diminuição das fibras colágenas perimisiais, aumento do número de mastócitos e aumento da imunomarcção para HIF-1 α nas células musculares linguais, pela primeira vez descritas. Sabendo da importância da musculatura lingual na deglutição, mastigação e fala o presente estudo chama a atenção para prevenção contra a exposição passiva ao tabaco.

Referências da Dissertação

ABONIA, J.P.; et al. Involvement of mast cells in eosinophilic esophagitis. **The Journal of Allergy and Clinical Immunology**, v. 126, n. 1, p. 140-9, 2010.

ASSIS, G.F.; et al. Cigarette smoke affects apoptosis in rat tongue mucosa: role of bcl-2 gene family. **Journal of Molecular Histology**, v. 36, n. 8-9, p. 483-9, 2005.

BARBOSA, K.B.; et al. Oxidative stress: concept, implications and modulating factors. **Revista de Nutrição**, v. 23, n. 629-643, 2010.

BARNOYA, J.; GLANTZ, S.A. Cardiovascular effects of secondhand smoke: nearly as large as smoking. **Circulation**, v. 111, n. 20, p. 2684–2698, 2005.

BEHERA, S.N.; XIAN, H.; BALASUBRAMANIAN, R. Human health risk associated with exposure to toxic elements in mainstream and sidestream cigarette smoke. **The Science of the Total Environment**, v. 15, n. 472, p. 947-56, 2014.

BERCHNER-PFANNSCHMIDT, U.; et al. Imaging of the hypoxia-inducible factor pathway: insights into oxygen sensing. **The European Respiratory Journal**, v. 32, n. 1, p. 210-7, 2008.

BROWN, M.A.; HATFIELD, J.K. Mast Cells are Important Modifiers of Autoimmune Disease: With so Much Evidence, Why is There Still Controversy?. **Frontiers in Immunology**, v. 7, n. 3, p. 147, 2012.

CARTY, C.S.; et al. Nicotine and cotinine stimulate secretion of basic fibroblast growth factor and affect expression of matrix metalloproteinases in cultured human smooth muscle cells. **Journal of Vascular Surgery**, v. 24, n. 6, 1996.

CHAICHALOTORNKUL, S., et al. Secondhand smoke exposure-induced nucleocytoplasmic shuttling of HMGB1 in a rat premature skin aging model. **Biochemical and Biophysical Research Communication**, v. 456, n. 1, p. 92-7, 2015.

COELHO, S.A.; ROCHA, S.A.; JONG, L.C. Consequências do tabagismo passivo em crianças. **Ciência Cuidado e Saúde**, V. 11, n. 2, p. 294-301, 2012.

COLLINGTON, S.J.; WILLIAMS, T.J.; WELLER, C.L. Mechanisms underlying the localisation of mast cells in tissues. **Trends in Immunology**, v. 32, n. 10, p. 478-85, 2011.

COLOMBO, G.; et al. Pathophysiology of tobacco smoke exposure: recent insights from comparative and redox proteomics. **Mass Spectrometry Reviews**, v. 33, n. 3, p. 183-218, 2014.

CONNOR, G.S.; et al. The accuracy of self-reported smoking: a systematic review of the relationship between self-reported and cotinine-assessed smoking status. **Nicotine and Tobacco Research**, v. 11, n. 1, p. 12-24, 2009.

CORRAINI, P.; et al. Risk indicators for increased probing depth in an isolated population in Brazil. **Journal of Periodontology**, v. 79, n. 9, p. 1726-34, 2008.

CRIVELLATO, E.; et al. The mast cell: an active participant or an innocent bystander. **Histology and Histopathology**, v. 19, n. 1, p. 259-70, 2004.

da SILVA, E.Z.; JAMUR, M.C.; OLIVER, C. Mast cell function: a new vision of an old cell. **The Journal of Histochemistry and Cytochemistry**, v. 62, n. 10 p. 698-738, 2014.

DAIJO, H.; et al. Cigarette smoke reversibly activates hypoxia-inducible factor 1 in a reactive oxygen species-dependent manner. **Scientific Reports**, v. 6, p. 34424, 2016.

de ARAÚJO MF; et al. Analysis of CD15, CD57 and HIF-1 α in biopsies of patients with peri-implantitis. **Pathology Research and Practice** v. 213, p. 1097-1101, 2017.

de LIMA PEREIRA, S.A.; et al. Quantitative analysis of fibrosis and mast cells in the tongue of chronic chagasic patients: autopsy study. **Médecine et Maladies Infectieuses**, v. 37, n. 4, p. 229-33, 2007.

De OLIVEIRA SEMENZATI, G.; et al. Histological and immunohistochemical study of the expression of p53 and ki-67 proteins in the mucosa of the tongue, pharynx and larynx of rats exposed to cigarette smoke. **Inhalation Toxicology**, v. 24, n. 11, p. 723-31, 2012.

DEPARTAMENTO DE INFORMÁTICA DO SUS. Centro Colaborador da OMS para a Classificação de Doenças em Português – CBCD. [Acesso em: 06 de Outubro de 2017]. Disponível em: <http://www.datasus.gov.br/cid10/V2008/cid10.htm>.

DOMAJ, W.; et al. Chronic obstructive pulmonary disease and oxidative stress. **Current Pharmaceutical Biotechnology**, v. 7, n. 2, p. 117-23, 2006.

DOUGHERTY, R.H.; et al. Accumulation of intraepithelial mast cells with a unique protease phenotype in T(H)2-high asthma. **The Journal of Allergy and Clinical Immunology**, v. 125, n. 5, p. 1046-1053, 2010.

FERRAGUT, J.M.; et al. Epithelial-stromal interactions in salivary glands of rats exposed to chronic passive smoking. **Archives of Oral Biology**, v. 56, n. 6, p. 580-7, 2011.

FEYERABEND, C.; et al. Determination of cotinine in biological fluids of nonsmoker by packed column gas liquid chromatography. **The Journal of Pharmacy and Pharmacology**, v. 38, p. 162-8, 1986.

FOWLES, J.; DYBING, E. Application of toxicological risk assessment principles to the chemical constituents of cigarette smoke. **Tobacco Control**, v. 12, n. 4, p. 424-30, 2003.

FUN, H.; et al. MMP-1/2 and TIMP-1/2 expression levels, and the levels of collagenous and elastic fibers correlate with disease progression in a hamster model of tongue cancer. **Oncology Letters**, v. 11, p. 63-68, 2016.

FURUKAWA, S.; UENO, M.; KAWAGUCHI, Y. Influence of tobacco on dental and oral diseases. **Nihon Rinsho**, v. 71, n. 3, p. 459-63, 2013.

GALLI, S.J.; et al. Mast cells as "tunable" effector and immunoregulatory cells: recent advances. **Annual Review of Immunology**, v. 23, p. 749-86, 2005.

GARTNER, L.P.; SAAD, A.Y.; HIATT, J.L. Effects of nicotine on tongue development in the CD-1 mouse. **European Journal of Morphology**, v. 35, n. 5, p. 337-43, 1997.

GELBMANN, C.M.; et al. Strictures in Crohn's disease are characterised by an accumulation of mast cells colocalised with laminin but not with fibronectin or vitronectin. **Gut**, v. 45, n. 2, p. 210-7, 1999.

GELSKEY, S.C. Cigarette smoking and periodontitis: methodology to assess the strength of evidence in support of a causal association. **Community Dentistry and Oral Epidemiology**, v. 27, n. 1, p. 16-24, 1999.

GENTNER, N.J.; WEBER, L.P. Secondhand tobacco smoke, arterial stiffness, and altered circadian blood pressure patterns are associated with lung inflammation and oxidative stress in rats. **American Journal of Physiology. Heart and Circulatory Physiology**, v. 302, n. 3, 2012.

GORDON, J.R.; BURD, P.R.; GALLI, S.J. Mast cells as a source of multifunctional cytokines. **Immunology Today**, v. 11, n. 12, p. 458-64, 1990.

GÖRTZ, G.E.; et al.. Hypoxia-Dependent HIF-1 Activation Impacts on Tissue Remodeling in Graves' Ophthalmopathy-Implications for Smoking. **The Journal of Clinical Endocrinology and Metabolism**, v. 101, n. 12, p. 4834-4842, 2016.

HOCHMAN, D.J.; COLLACO, C.R.; BROOKS, E.G. Acrolein induction of oxidative stress and degranulation in mast cells. **Environmental Toxicology**, v. 29, n. 8, p. 908-15, 2008.

HOFFMANN, D.; HOFFMANN, I.; EL-BAYOUMY, K. The less harmful cigarette: A controversial issue. a tribute to Ernst L. Wynder. **Chemical Research in Toxicology**, v. 14, p. 767–790, 2001.

INSTITUTO BRASILEIRO DE GEOGRAFIA E ESTATÍSTICA. Pesquisa Nacional por Amostra de Domicílios 2008. **IBGE**, p.49, 2008. [Acesso em: 10 de Abril de 2017]. Disponível em: <https://biblioteca.ibge.gov.br/visualizacao/monografias/GEBIS%20-%20RJ/panorama.pdf>

IRANI, A.A.; et al. Two types of human mast cells that have distinct neutral protease compositions. **Proceedings of the National Academy of Sciences of the United States of America**, v. 83, n. 12, p. 4464-8, 1986.

JABER, M.A. Tobacco smoking and alcohol consumption as risk factors for site-specific intra oral epithelial dysplasia. **Journal of Investigative and Clinical Dentistry**, v. 1, n. 2, p. 101-7, 2010.

JARVIS, M.J.; et al. Comparison of tests used to distinguish smokers from nonsmokers. **American Journal of Public Health**, v. 77, n. 11, p. 1435-1438, 1987.

JENNE, D.E.; TSCHOPP, J. Angiotensin II-forming heart chymase is a mast-cell-specific enzyme. **The Biochemical Journal**, v.276,p. 567-8, 1991.

JEONG, H.J.; et al. The critical role of mast cell-derived hypoxia-inducible factor-1a in human and mice melanoma growth. **International Journal of Cancer**, v. 132, p. 2492-2501, 2013.

JO, Y.H.; TALMAGE, D.A.; ROLE, L.W. Nicotinic receptor-mediated effects on appetite and food intake. **Journal of Neurobiology**, v. 53, p. 618-32, 2002.

JUNG, S.; et al. Urine cotinine for assessing tobacco smoke exposure in Korean: analysis of the Korea National Health and Nutrition Examination Survey (KNHANES). **Tuberculosis and Respiratory Diseases**, v. 73, n. 4, p. 210-218, 2012.

KERKELÄ, E.; SAARIALHO-KERE, U. Matrix metalloproteinases in tumor progression: focus on basal and squamous cell skin cancer. **Experimental Dermatology**, v. 12, p. 109-125, 2003.

KISPERT, S.; et al. In Vivo Effects of Long-Term Cigarette Smoke Exposure on Mammary Tissue in Mice. **The American Journal of Pathology**, v. 187, n. 6, 2017.

LEE, K.I.; et al. Cigarette smoke promotes eosinophilic inflammation, airway remodeling, and nasal polyps in a murine polyp model. **American Journal of Rhinology and Allergy**, v. 28, n. 3, p. 208-14, 2014.

LEONE, A. Toxics of Tobacco Smoke and Cardiovascular System: From Functional to Cellular Damage. **Current Pharmaceutical Design**, v. 21, n. 30, p. 4370-9, 2015.

LI, H.; et al. Cancer-associated fibroblasts provide a suitable microenvironment for tumor development and progression in oral tongue squamous cancer. **Journal of Translational Medicine**, v. 13, p. 198, 2015.

MARTINS, R.H.; et al. Scanning electron microscopy of the tongue, pharynx, and larynx of rats exposed to cigarette smoke. **Journal of Voice: Official Journal of the Voice Foundation**, v. 28, n. 3, p. 287-90, 2014.

MATSSON, L. Mast cell heterogeneity in various oral mucosal sites in the rat. **Archives of Oral Biology**, v. 37, n. 6, p. 445-50, 1992.

MATT, G.E.; et al. When smokers quit: exposure to nicotine and carcinogens persists from thirdhand smoke pollution. **Tobacco Control**, v. 26, n. 5, p. 548-556, 2016.

MELLO, P.R.B.; et al. Evaluation of experimental tobacco exposure using cotinine and carboxyhemoglobin as exposure markers. **Pulmão RJ**, v. 14, n. 3, p. 228–236, 2005.

METACALFE, D.D. Mast cells and mastocytosis. **Blood**, v. 112, n. 4, p. 946-56, 2008.

MILLER, J.L.; WATKIN, K.L.; CHEN, M.F. Muscle, adipose, and connective tissue variations in intrinsic musculature of the adult human tongue. **Journal of Speech, Language and Hearing Research**, v. 45, n. 1, p. 51-65, 2002.

MIYANG, J.; et al. The acute effect of smoking a single cigarette on vascular status, SpO₂, and stress level. **Medical Science Monitor: International Medical Journal of Experimental and Clinical Research**, v. 20, p. 601-7, 2014.

MOORE, S.R.; et al. The epidemiology of tongue cancer: a review of global incidence. **Oral Diseases**, v. 6, n. 2, p. 75-84, 2000.

MORTAZ, E.; et al. A relation between TGF- β and mast cell tryptase in experimental emphysema models. **Biochimica et Biophysica Acta**, v. 1822, n. 7, p. 1154-60, 2012.

MORTAZ, E.; et al. Cigarette smoke stimulates the production of chemokines in mast cells. **Journal of Leukocyte Biology**, v. 83, n. 3, p. 575-80, 2008.

NATIONAL RESEARCH COUNCIL (NRC). Guide for the Care and Use of Laboratory Animals: Eighth Edition. Washington, DC: The National Academies Press. 2011. [Acesso em: 14 de Abril de 2017]. Disponível em: <https://doi.org/10.17226/12910>.

OBERG, M.; et al. Worldwide burden of disease from exposure to second-hand smoke: a retrospective analysis of data from 192 countries. **Lancet**, v. 8, n. 377, p. 139-46. 2011.

PARADA, C.; HAN, D.; CHAI, Y. Molecular and cellular regulatory mechanisms of tongue myogenesis. **Journal of Dental Research**, v. 91, n. 6, p. 528-535, 2012.

PERFETTI, T.A.; RODGMAN, A. The Complexity of Tobacco and Tobacco Smoke. **The Journal of BTFI GmbH**, v. 4, n. 25, 2011.

PESQUISA NACIONAL DE SAÚDE (PNS) – **Módulo e Estilo de Vida – Uso de Álcool e Tabagismo**. 2013. [Acesso em: 20 de Março de 2017]. Disponível em: http://tabnet.datasus.gov.br/cgi/pns/Notas_Tecnicas_PNS_P_F.pdf.

PETERSEN, G.O.; et al. Cotinine as a biomarker of tobacco exposure: development of a HPLC method and comparison of metrics. **Journal of Separation Science**, v. 33, n. 4-5, 2010.

RAJA, M.; et al. Diagnostic Methods for Detection of Cotinine Level in Tobacco Users: A Review. **Journal of Clinical and Diagnostic Research**, v. 10, n. 3, p. ZE04-6, 2016.

RAMALHO, L.S.; et al. Role of mast cell chymase and tryptase in the progression of atherosclerosis: study in 44 autopsied cases. **Annals of Diagnostic Pathology**, v. 17, n. 1, p. 28-31, 2013.

REIBEL, J. Tobacco and oral diseases. update on the evidence with recommendations. **Medical Principles and Practice**, v. 12, n. 1, p. 22-32, 2003.

SANDERS, I.; MU, L. A 3-Dimensional Atlas of Human Tongue Muscles. **The Anatomical Record: Advances in Integrative Anatomy and Evolutionary Biology**, v. 296, n. 7, p. 1102-1114, 2013.

SANTIAGO, H.A.; et al. Exposure to Secondhand Smoke Impairs Fracture Healing in Rats. **Clinical Orthopaedics Related Research**, v. 475, n. 3, p. 894-902, 2017.

SCHICK, S.; GLANTZ, S. Philip Morris toxicological experiments with fresh sidestream smoke: more toxic than mainstream smoke. **Tobacco Control**, v. 14, n. 6, p. 396-404. 2005.

SCHWARTZ, L.B. Analysis of MC(T) and MC(TC) mast cells in tissue. **Methods in Molecular Biology**, v. 315, p. 53-62, 2006.

SEMBEROVA, J.; et al. The immune status in situ of recurrent tonsillitis and idiopathic tonsillar hypertrophy. **Bratislavské Lekárske Listy**, v. 114, n. 3, p. 140-4, 2013.

SEMENZA, G.L. Hydroxylation of HIF-1: oxygen sensing at the molecular level. **Physiology (Bethesda)**, v. 19, p. 176-82, 2004.

SHAM, A.S.; et al. The effects of tobacco use on oral health. **Hong Kong Medical Journal**, v. 9, n. 4, p. 271-7, 2003.

SHAMMARI, A.F.; et al. Effects of Tobacco Smoking on the Dorsum of the Tongue and Buccal Epithelium. **Asian Pacific Journal of Cancer Prevention**, v. 17, n. 10, p. 4713-4718, 2016.

SINGH, S.P.; et al. HIF-1 α Plays a Critical Role in the Gestational Sidestream Smoke-Induced Bronchopulmonary Dysplasia in Mice. **PLoS One**, v. 10, n. 9, p. e0137757, 2015.

SOPORI, M.L.; KOZAK, W. Immunomodulatory effects of cigarette smoke. **Journal of Neuroimmunology**, v. 15, n. 83, p. 148-56, 1998.

SUSIN, C.; et al. Periodontal attachment loss attributable to cigarette smoking in an urban Brazilian population. **Journal of Clinical Periodontology**, v. 31, n. 11, p. 951-8, 2004.

SUZUKI, A.; et al. N-Cadherin Plays a Role in the Synapse-Like Structures between Mast Cells and Neurites. **Biological and Pharmaceutical Bulletin**, v.27, n. 12, p. 1891-1894, 2004.

TAYLOR, C.T.; COLGAN, S.P. Regulation of immunity and inflammation by hypoxia in immunological niches. **Nature Reviews Immunology**, Oct. 2017.

THORNE, D.; ADAMSON, J. A review of in vitro cigarette smoke exposure systems. **Experimental Toxicology Pathology**, v. 65, n. 7-8, p. 1183-93, 2013.

VALENÇA, S.S.; PORTO, L.C. Immunohistochemical study of lung remodeling in mice exposed to cigarette smoke. **Jornal Brasileiro de Pneumologia**, v. 34, n. 10, p. 787-95, 2008.

VALENTI, V.E.; Sidestream Cigarette Smoke Exposure Effects on Baroreflex in Adult Rats. **Arquivos Brasileiros de Cardiologia**, v. 96, n. 2, p. 148-53.

WAGNER, K.; et al. Blunt Chest Trauma in Mice after Cigarette Smoke-Exposure: Effects of Mechanical Ventilation with 100% O₂. **PLoS One**, v. 10, n. 7, p. e0132810, 2015.

WANG, X.D.; et al. Retinoid signaling and activator protein-1 expression in ferrets given beta-carotene supplements and exposed to tobacco smoke. **Journal of National Cancer Institute**, v. 91, n. 1, Jan. 1999.

WARNAKULASURIYA, S.; et al. Oral health risks of tobacco use and effects of cessation. **International Dental Journal**, v. 60, n. 1, p. 7-30, 2010.

WEI, X.M.; et al. Effects of cigarette smoke on degranulation and NO production by mast cells and epithelial cells. **Respiratory Research**, v. 19, n. 6, p. 108, 2005.

WORLD HEALTH ORGANIZATION (WHO). **Tobacco: relatório n° 339 de julho de 2015**. [Acesso em: 25 de Março de 2017]. Disponível em: <http://www.who.int/mediacentre/factsheets/fs339/en/>.

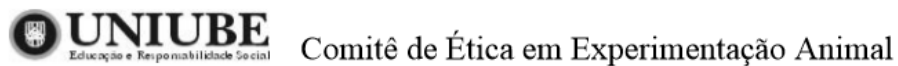
WU, J.P.; et al. Secondhand smoke exposure toxicity accelerates age-related cardiac disease in old hamsters. **BMC Cardiovascular Disorders**, v. 14, p.195, 2014

YOSHIDA, R.; et al. Genetic polymorphisms in human CYP2A6 gene causing impaired nicotine metabolismo. **British Journal of Clinical Pharmacology**, v. 54, n. 5, p. 511-517, 2002.

YU, H.; et al. Regulation of cigarette smoke-mediated mucin expression by hypoxia-inducible factor-1 α via epidermal growth factor receptor-mediated signaling pathways. **Journal of Applied Toxicology**, v. 32, n. 4, p. 282-92, 2012.

ZHANG, Q.; et al. Nicotine induces hypoxia-inducible factor-1 α expression in human lung cancer cells via nicotinic acetylcholine receptor-mediated signaling pathways. **Clinical Cancer Research**, v. 13, n. 16, p. 4686-94, 2007.

Anexo I



Ofício CEEA-070/2017

Uberaba, 1 de dezembro de 2017

Ilma Profa.

Sanívia Aparecida de Lima Pereira

Assunto: Encaminha processo nº 024/2017, sobre o protocolo de pesquisa "Análise histopatológica do tecido epitelial e da musculatura da língua de ratas, submetidas a inalação da fumaça do tabaco".

Prezado(a) Professor(a),

Em resposta a sua solicitação, informo que o protocolo acima referido foi submetido avaliação do CEEA-UNIUBE, na reunião do dia 20/09/2017, sendo considerado **aprovado**.

Atenciosamente,

**Prof. Joly F. Figueiredo Bittar**

Coordenadora do CEEA-UNIUBE

Anexo II

Figura 1

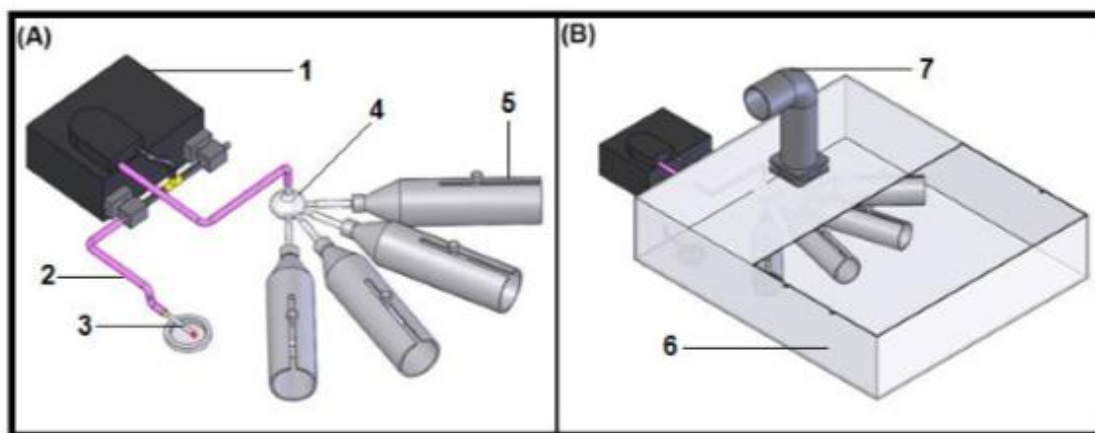


Figura 1. (A) Desenho esquemático do sistema usado para expor os animais à fumaça do cigarro. Bomba peristáltica [1], tubulação [2], cigarro [3], recipiente esférico para distribuição da fumaça [4] e os tubos cilíndricos [5], onde os animais ficaram contidos. (B) Desenho esquemático da caixa externa isolante [6] e exaustor para o meio externo [7] (imagem fornecida pelo Laboratório de Bioengenharia da Faculdade de Medicina de Ribeirão Preto [2015]).

Anexo III

Journal: Inhalation Toxicology Instructions for authors Updated April 2016

Thank you for choosing to submit your paper to us. These instructions will ensure we have everything required so your paper can move through peer review, production and publication smoothly. Please take the time to read and follow them as closely as possible, as doing so will ensure your paper matches the journal's requirements. For general guidance on the publication process at Taylor & Francis please visit our Author Services website.

This journal uses ScholarOne Manuscripts (previously Manuscript Central) to peer review manuscript submissions. Please read the guide for ScholarOne authors before making a submission. Complete guidelines for preparing and submitting your manuscript to this journal are provided below.

About the journal

Inhalation Toxicology is an international, peer reviewed journal, publishing high-quality, original research. Please see the journal's Aims & Scope for information about its focus and peer-review policy.

Please note that this journal only publishes manuscripts in English.

This journal accepts the following article types: original papers, reviews, measurement technology, modelling/symmetry and letters to the Editor.

Peer review

Taylor & Francis is committed to peer-review integrity and upholding the highest standards of review. Once your paper has been assessed for suitability by the editor, it will then be single blind peer-reviewed by independent, anonymous expert referees. Find out more about what to expect during peer review and read our guidance on publishing ethics.

Preparing your paper

All authors submitting to medicine, biomedicine, health sciences, allied and public health journals should conform to the Uniform Requirements for Manuscripts Submitted to Biomedical Journals, prepared by the International Committee of Medical Journal Editors (ICMJE).

Structure

Your paper should be compiled in the following order: title page; abstract; keywords; main text: introduction, methods, results, discussion, conclusion; acknowledgments; declaration of interest statement; references; appendices (as appropriate); table(s) with caption(s) (on individual pages); figures; figure captions (as a list).

Word count

Please include a word count for your paper. A typical paper for this journal should not

exceed 12000 words; inclusive of tables, references, figure captions.

Style guidelines

Please refer to these style guidelines when preparing your paper, rather than any published articles or a sample copy.

Please use American spelling consistently throughout your manuscript.

Please use single quotation marks, except where 'a quotation is "within" a quotation'. Please note that long quotations should be indented without quotation marks.

Formatting and templates

Papers may be submitted in any standard format, including Word and LaTeX. Figures should be saved separately from the text. To assist you in preparing your paper, we provide formatting template(s).

Word templates are available for this journal. Please save the template to your hard drive, ready for use.

If you are not able to use the templates via the links (or if you have any other template queries) please contact authortemplate@tandf.co.uk

References

Please use this reference guide when preparing your paper. An EndNote output style is also available to assist you.

Checklist: what to include

Author details. Please ensure everyone meeting the International Committee of Medical Journal Editors (ICJME) requirements for authorship is included as an author of your paper. Please include all authors' full names, affiliations, postal addresses, telephone numbers and email addresses on the cover page. Where available, please also include ORCIDiDs and social media handles (Facebook, Twitter or LinkedIn). One author will need to be identified as the corresponding author, with their email address normally displayed in the article PDF (depending on the journal) and the online article. Authors' affiliations are the affiliations where the research was conducted. If any of the named co-authors moves affiliation during the peer-review process, the new affiliation can be given as a footnote. Please note that no changes to affiliation can be made after your paper is accepted. Read more on authorship.

A structured abstract should cover (in the following order).

A structured abstract of no more than 250 words. A structured abstract should cover (in the following order): its objective, its materials and methods (the experimental system and procedures used), the results and discussion and conclusions. Read tips on writing your abstract.

You can opt to include a video abstract with your article. Find out how these can help your work reach a wider audience, and what to think about when filming.

5-10 keywords. Read making your article more discoverable, including information on choosing a title and search engine optimization.

Funding details. Please supply all details required by your funding and grant-awarding bodies as follows: For single agency grants: This work was supported <funding agency=""> under Grant <number xxxx="">. For multiple agency grants: This work was supported by the <funding agency="" 1=""> under Grant <number xxxx=""> <funding agency="" 2=""> under Grant <number xxxx=""> and <funding agency="" 3=""> under Grant <number xxxx="">.

Disclosure statement. This is to acknowledge any financial interest or benefit that has arisen

from the direct applications of your research. Further guidance on what is a conflict of interest and how to disclose it.

Geolocation information. Submitting a geolocation information section, as a separate paragraph before your acknowledgements, means we can index your paper's study area accurately in JournalMap's geographic literature database and make your article more discoverable to others. More information.

Supplemental online material. Supplemental material can be a video, dataset, fileset, sound file or anything which supports (and is pertinent to) your paper. We publish supplemental material online via Figshare. Find out more about supplemental material and how to submit it with your article.

Figures. Figures should be high quality (1200 dpi for line art, 600 dpi for grayscale and 300 dpi for colour). Figures should be saved as TIFF, PostScript or EPS files.

Tables. Tables should present new information rather than duplicating what is in the text. Readers should be able to interpret the table without reference to the text. Please supply editable files.

Equations. If you are submitting your manuscript as a Word document, please ensure that equations are editable. More information about mathematical symbols and equations.

Units. Please use SI units (non-italicized).

Using third-party material in your paper

You must obtain the necessary permission to reuse third-party material in your article. The use of short extracts of text and some other types of material is usually permitted, on a limited basis, for the purposes of criticism and review without securing formal permission. If you wish to include any material in your paper for which you do not hold copyright, and which is not covered by this informal agreement, you will need to obtain written permission from the copyright owner prior to submission. More information on requesting permission to reproduce work(s) under copyright.

Disclosure statement

Please include a disclosure of interest statement, using the subheading "Disclosure of interest." If you have no interests to declare, please state this (suggested wording: The authors report no conflicts of interest). For all NIH/Wellcome-funded papers, the grant number(s) must be included in the disclosure of interest statement. Read more on declaring conflicts of interest.

Clinical Trials Registry

In order to be published in a Taylor & Francis journal, all clinical trials must have been registered in a public repository at the beginning of the research process (prior to patient enrolment). Trial registration numbers should be included in the abstract, with full details in the methods section. The registry should be publicly accessible (at no charge), open to all prospective registrants, and managed by a not-for-profit organization. For a list of registries that meet these requirements, please visit the WHO International Clinical Trials Registry Platform (ICTRP). The registration of all clinical trials facilitates the sharing of information among clinicians, researchers, and patients, enhances public confidence in research, and is in accordance with the ICMJE guidelines.

Complying with ethics of experimentation

Please ensure that all research reported in submitted papers has been conducted in an

ethical and responsible manner, and is in full compliance with all relevant codes of experimentation and legislation. All papers which report in vivo experiments or clinical trials on humans or animals must include a written statement in the Methods section. This should explain that all work was conducted with the formal approval of the local human subject or animal care committees (institutional and national), and that clinical trials have been registered as legislation requires. Authors who do not have formal ethics review committees should include a statement that their study follows the principles of the Declaration of Helsinki.

Consent

All authors are required to follow the ICMJE requirements on privacy and informed consent from patients and study participants. Please confirm that any patient, service user, or participant (or that person's parent or legal guardian) in any research, experiment, or clinical trial described in your paper has given written consent to the inclusion of material pertaining to themselves, that they acknowledge that they cannot be identified via the paper; and that you have fully anonymized them. Where someone is deceased, please ensure you have written consent from the family or estate. Authors may use this Patient Consent Form, which should be completed, saved, and sent to the journal if requested.

Health and safety

Please confirm that all mandatory laboratory health and safety procedures have been complied with in the course of conducting any experimental work reported in your paper. Please ensure your paper contains all appropriate warnings on any hazards that may be involved in carrying out the experiments or procedures you have described, or that may be involved in instructions, materials, or formulae.

Please include all relevant safety precautions; and cite any accepted standard or code of practice. Authors working in animal science may find it useful to consult the International Association of Veterinary Editors' Consensus Author Guidelines on Animal Ethics and Welfare and Guidelines for the Treatment of Animals in Behavioural Research and Teaching. When a product has not yet been approved by an appropriate regulatory body for the use described in your paper, please specify this, or that the product is still investigational.

Submitting your paper

This journal uses This journal uses ScholarOne to manage the peer-review process. If you haven't submitted a paper to this journal before, you will need to create an account in the submission centre. Please read the guidelines above and then submit your paper in the relevant Author Centre, where you will find user guides and a helpdesk.

If you are submitting in LaTeX, please convert the files to PDF beforehand (you will also need to upload your LaTeX source files with the PDF).

Please note that Inhalation Toxicology uses Crossref™ to screen papers for unoriginal material. By submitting your paper to Inhalation Toxicology you are agreeing to originality checks during the peer-review and production processes.

On acceptance, we recommend that you keep a copy of your Accepted Manuscript. Find out more about sharing your work.

Publication charges

There are no submission fees or page charges for this journal.

Color figures will be reproduced in color in your online article free of charge. If it is necessary for the figures to be reproduced in color in the print version, a charge will apply.

Charges for color figures in print are £250 per figure (\$395 US Dollars; \$385 Australian Dollars; €315). For more than 4 color figures, figures 5 and above will be charged at £50 per figure (\$80 US Dollars; \$75 Australian Dollars; €63). Depending on your location, these charges may be subject to local taxes.

Copyright options

Copyright allows you to protect your original material, and stop others from using your work without your permission. Taylor & Francis offers a number of different license and reuse options, including Creative Commons licenses when publishing open access. Read more on publishing agreements.

Complying with funding agencies

We will deposit all National Institutes of Health or Wellcome Trust-funded papers into PubMedCentral on behalf of authors, meeting the requirements of their respective open access (OA) policies. If this applies to you, please tell our production team when you receive your article proofs, so we can do this for you. Check funders' OA policy mandates here. Find out more about sharing your work.

Open access

This journal gives authors the option to publish open access via our Open Select publishing program, making it free to access online immediately on publication. Many funders mandate publishing your research open access; you can check open access funder policies and mandates here.

Taylor & Francis Open Select gives you, your institution or funder the option of paying an article publishing charge (APC) to make an article open access. Please contact openaccess@tandf.co.uk if you would like to find out more, or go to our Author Services website.

For more information on license options, embargo periods and APCs for this journal please go here.

Accepted Manuscripts Online (AMO)

This journal publishes manuscripts online as rapidly as possible, as a PDF of the final, accepted (but unedited and uncorrected) paper. This is clearly identified as an unedited manuscript and is referred to as the Accepted Manuscript Online (AMO). No changes will be made to the content of the original paper for the AMO version but, after copy-editing, typesetting, and review of the resulting proof, the final corrected version (the Version of Record [VoR]), will be published, replacing the AMO version.

The VoR is the article version that will appear in an issue of the journal. Both the AMO version and VoR can be cited using the same DOI (digital object identifier). To ensure rapid publication, we ask you to return your signed publishing agreement as quickly as possible, and return corrections within 48 hours of receiving your proofs.

My Authored Works

On publication, you will be able to view, download and check your article's metrics

(downloads, citations and Altmetric data) via My Authored Works on Taylor & Francis Online. This is where you can access every article you have published with us, as well as your free eprints link, so you can quickly and easily share your work with friends and colleagues.

We are committed to promoting and increasing the visibility of your article. Here are some tips and ideas on how you can work with us to promote your research.

Article reprints

For enquiries about reprints, please contact the Taylor & Francis Author Services team at reprints@tandf.co.uk. To order a copy of the issue containing your article, please contact our Customer Services team at Adhoc@tandf.co.uk.

Sponsored supplements

This journal occasionally publishes sponsored supplements alongside its schedule of regular issues. Like our articles, all our supplements are expected to meet the same editorial standards as the journal and are subject to approval of the Editor prior to acceptance. They are indexed by the journal and offer targeted, cost-effective and high-impact reach. For more information and to discuss your requirements, please contact charles.whalley@tandf.co.uk.

Queries

Should you have any queries, please visit our Author Services website or contact us at authorqueries@tandf.co.uk.

Anexo IV

Inhalation Toxicology



Histopathological analysis of the epithelial tissue and tongue musculature of rats submitted to inhalation of tobacco smoke

Journal:	Inhalation Toxicology
Manuscript ID	Draft
Manuscript Type:	Research Article
Date Submitted by the Author:	n/a
Complete List of Authors:	de Paula Amaral, Eleonora; Universidade de Uberaba César Rosa, Rodrigo; Universidade Federal do Triângulo Mineiro Margarida Etchebehere, Renata; Universidade Federal do Triângulo Mineiro Dias Nogueira, Ruchele; Universidade de Uberaba Batista Volpon, José ; Universidade de Sao Paulo Faculdade de Medicina de Ribeirão Preto Bertulucci Rocha Rodrigues, Denise; Universidade de Uberaba Aparecida de Lima Pereira. Sanívia: sanivia.pereira@uniube.br.

SCHOLARONE™
Manuscripts

URL: <http://mc.manuscriptcentral.com/uiht>

Anexo V

05/02/2018

ScholarOne Manuscripts

 Inhalation Toxicology[Home](#)[Author](#)[Review](#)

Submission Confirmation

[Print](#)

Thank you for your submission

Submitted to
Inhalation Toxicology

Manuscript ID
UIHT-2018-0018

Title
Histopathological analysis of the epithelial tissue and tongue musculature of rats submitted to inhalation of tobacco smoke

Authors
de Paula Amaral, Eleonora
César Rosa, Rodrigo
Margarida Elchebehere, Renata
Dias Nogueira, Ruchele
Batista Volpon, José
Bertulucci Rocha Rodrigues, Denise
Aparecida de Lima Pereira, Saniya

Date Submitted
05-Feb-2018

[Author Dashboard](#)

Apêndice

Figura 2A e 2B

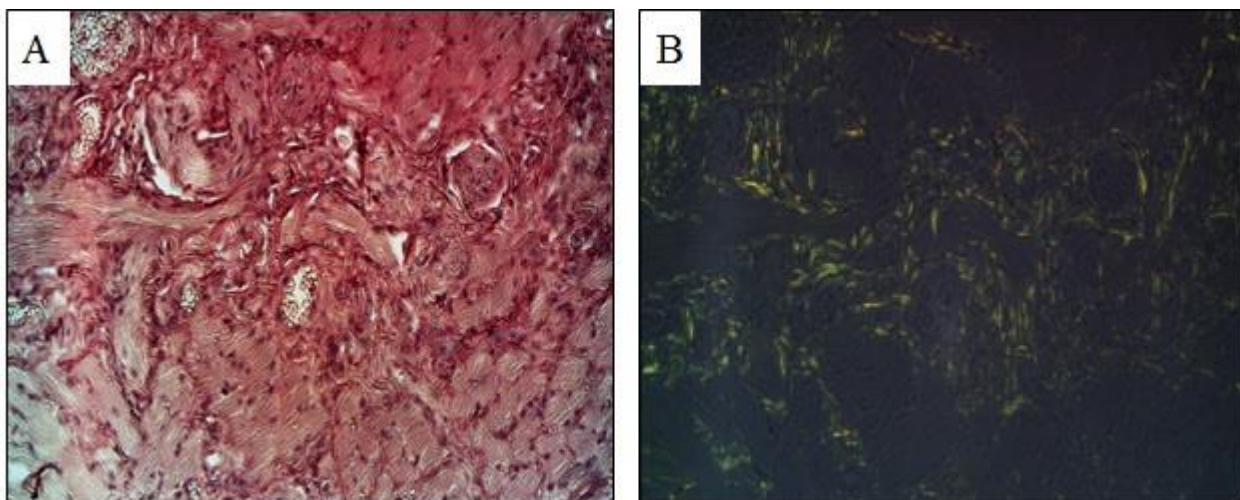


Figura 3

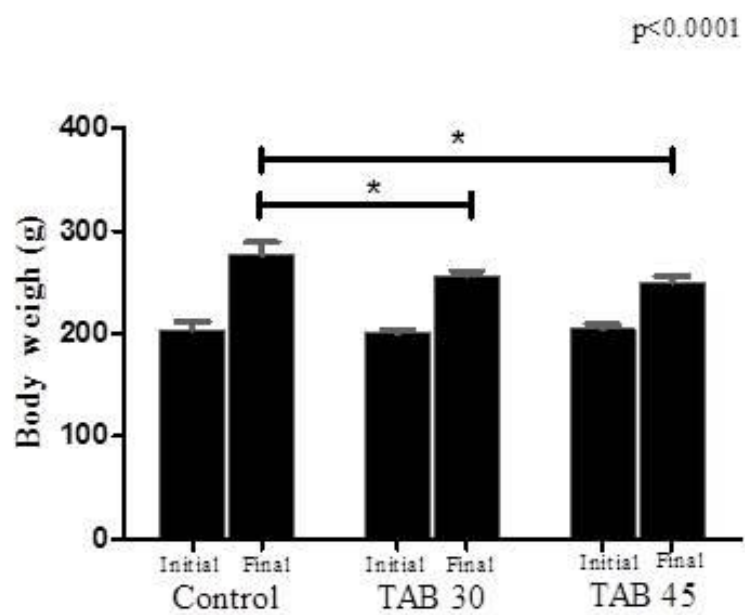


Figura 4A e 4B

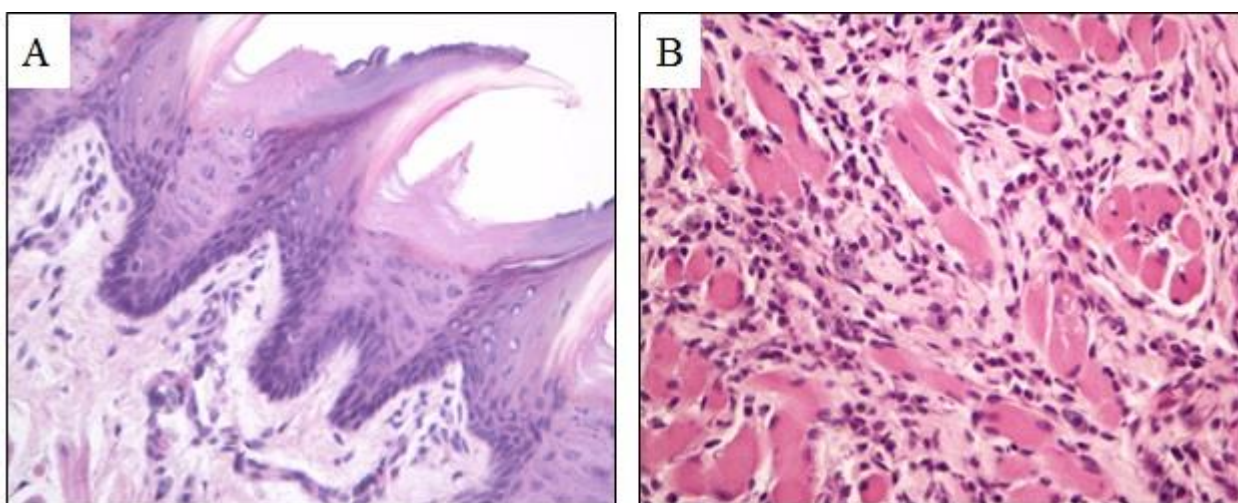


Figura 5

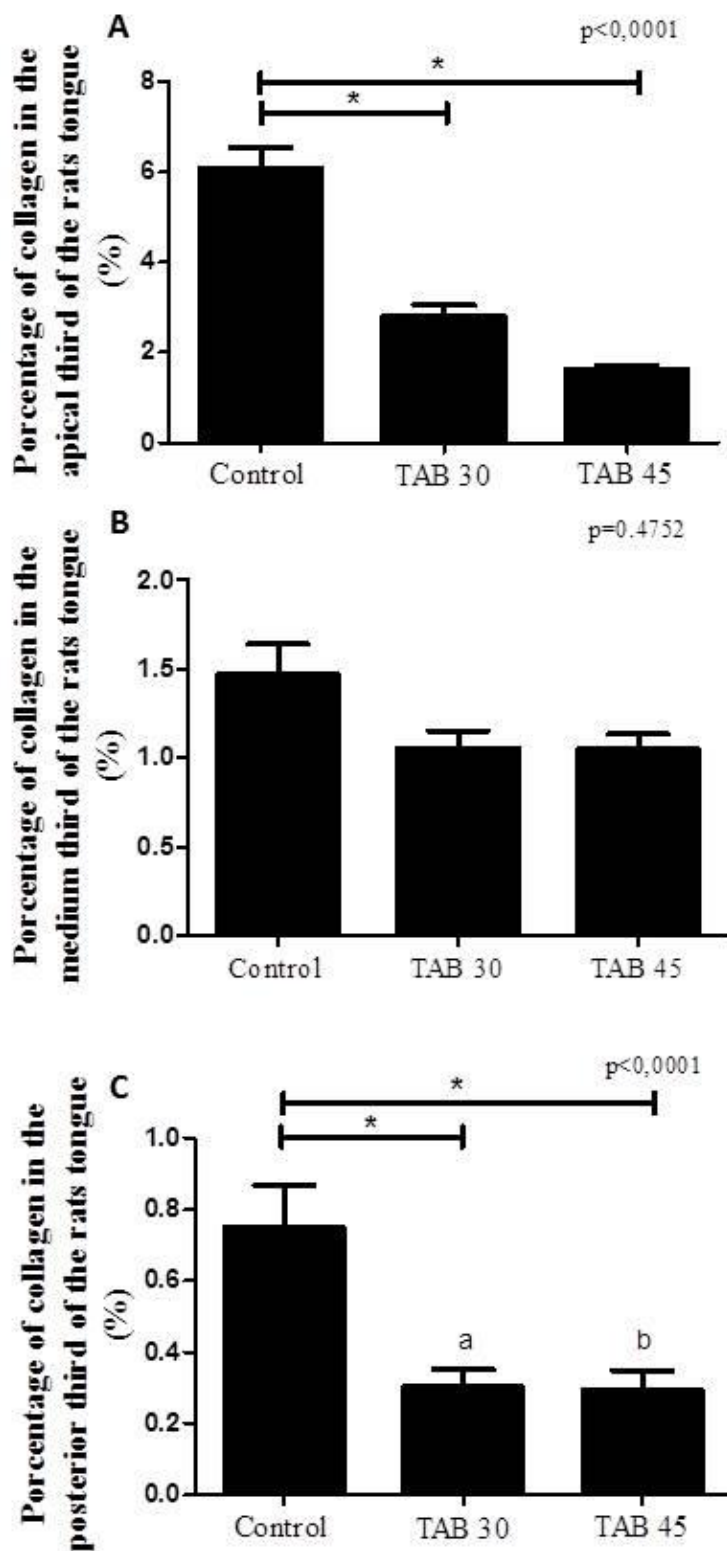


Figura 6

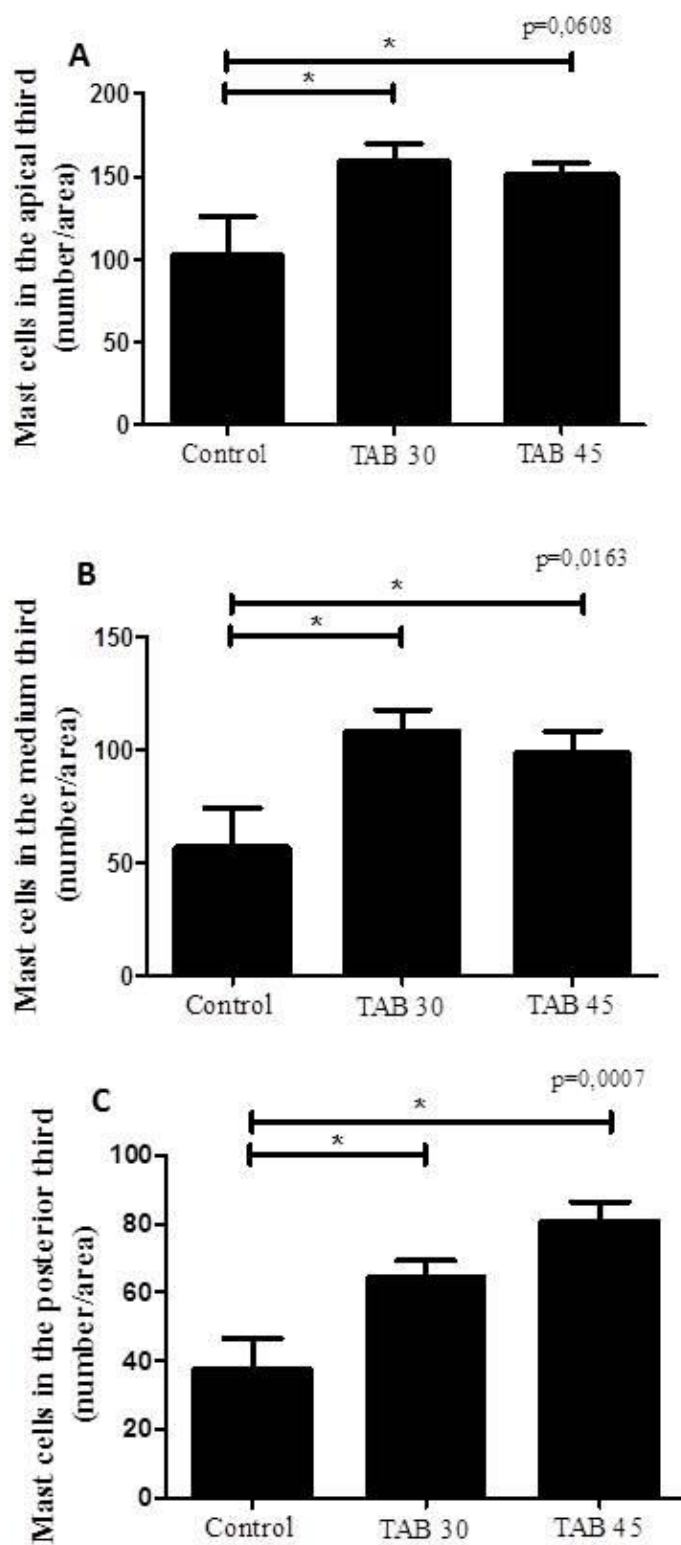


Figura 7

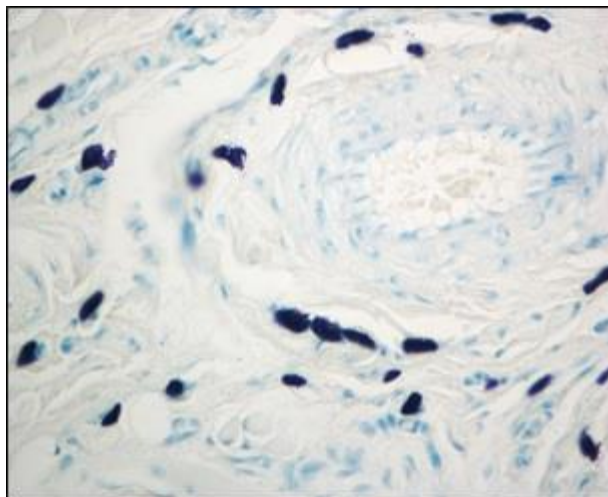


Figura 8A e 8B

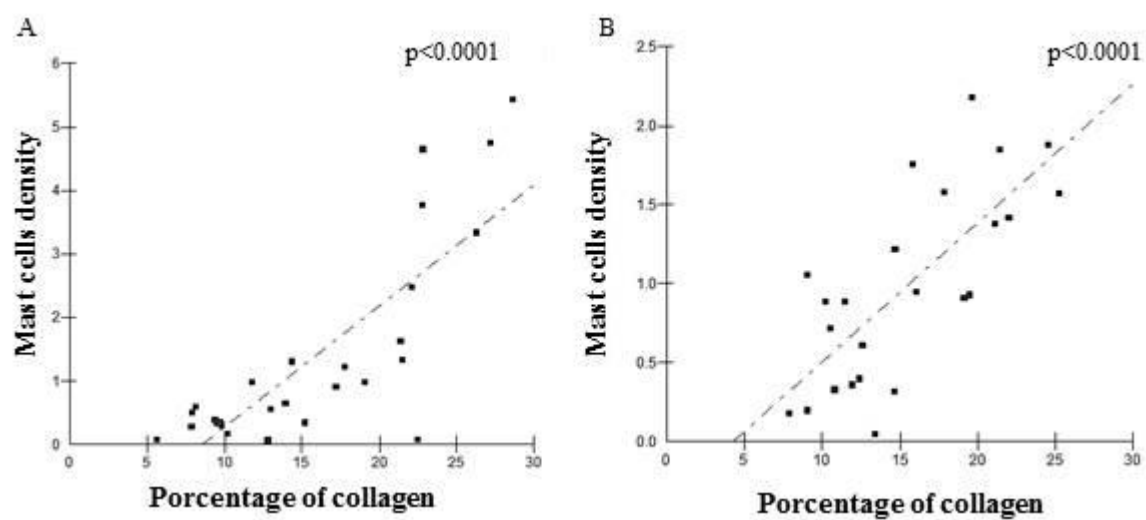


Figura 9

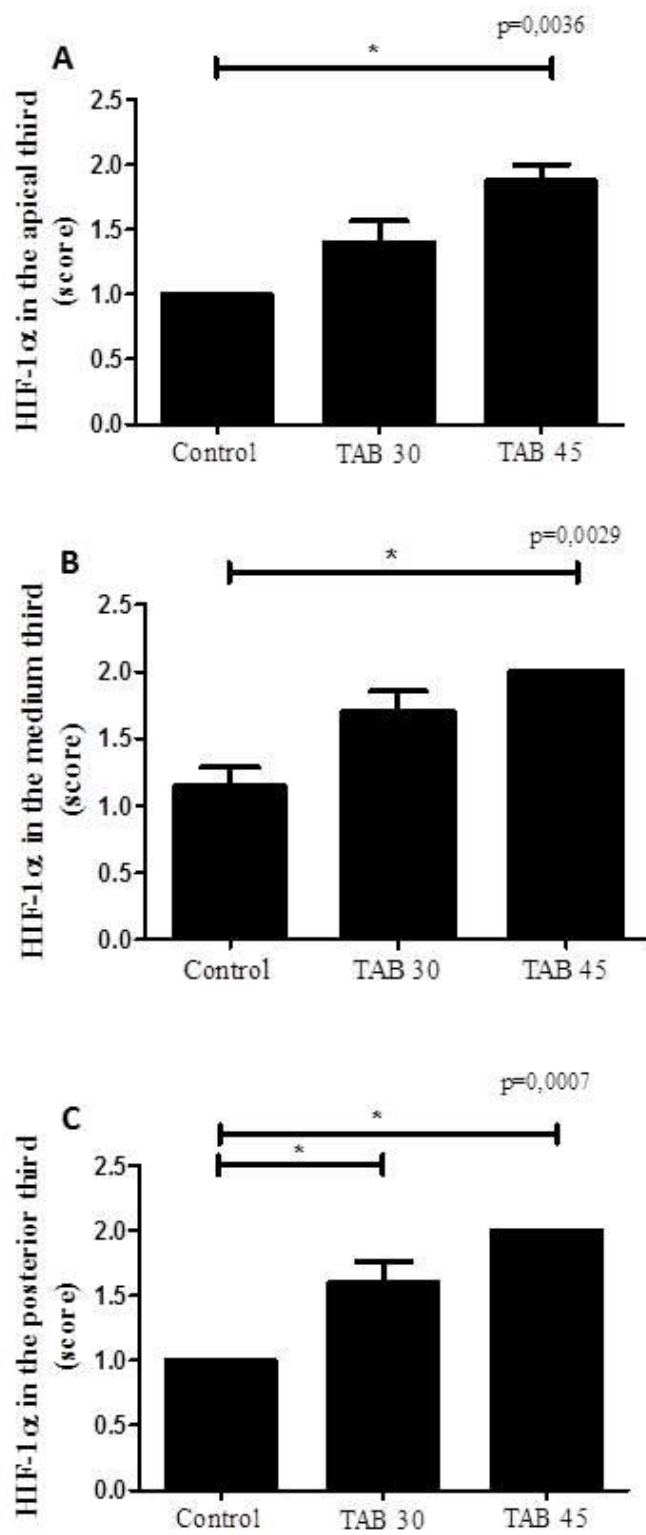


Figure 10

